

# THE ARTISTRY OF **INJECTABLES**

Comprehensive Training For Your Practice

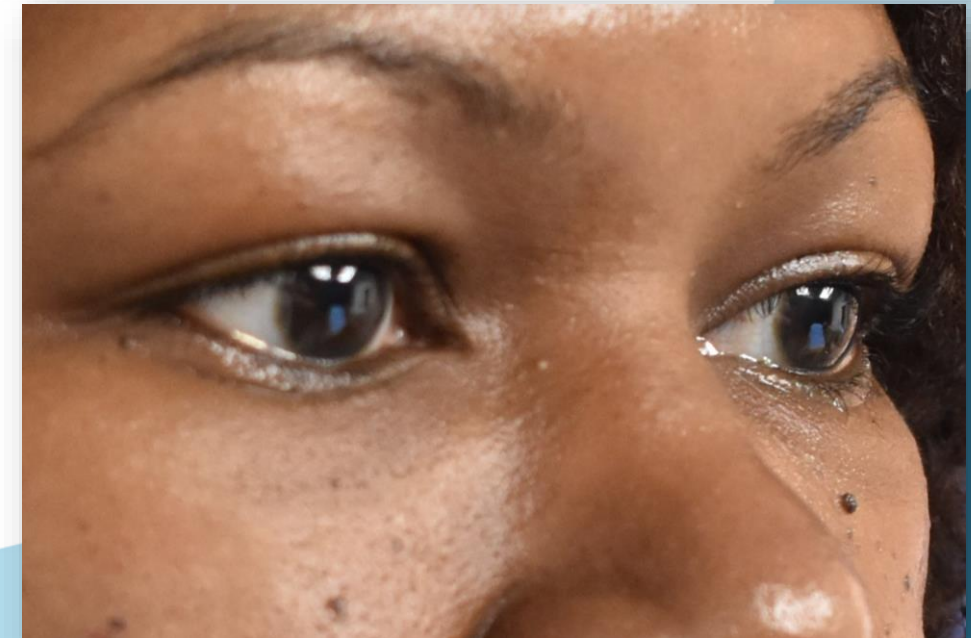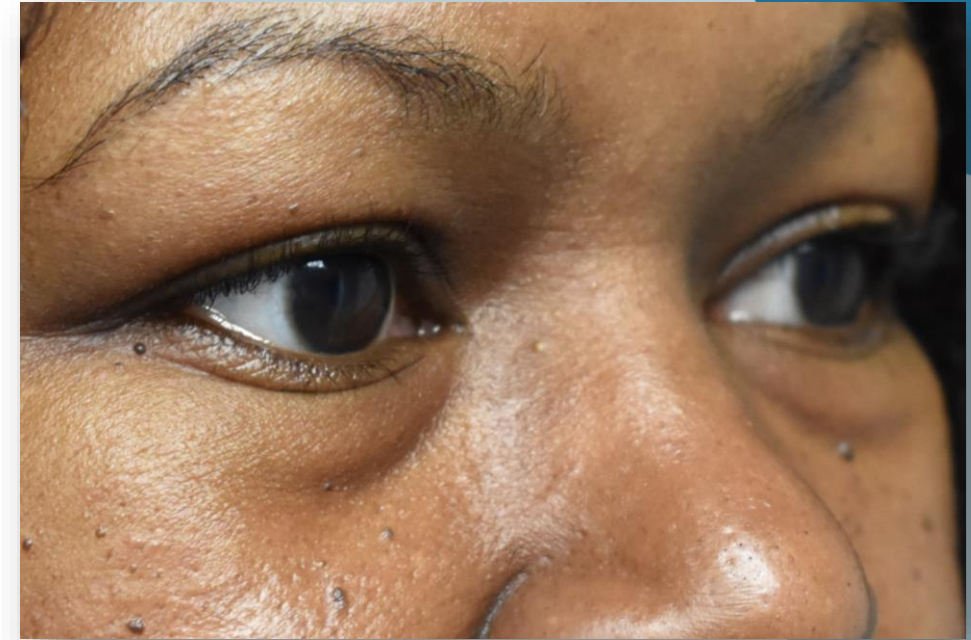## Correction of Infraorbital Hollows

Karol A Gutowski, MD, FACS

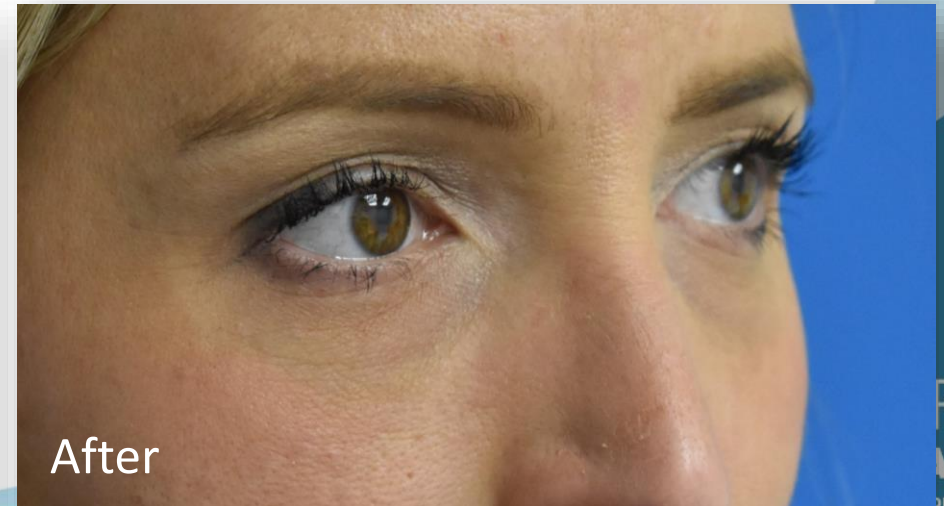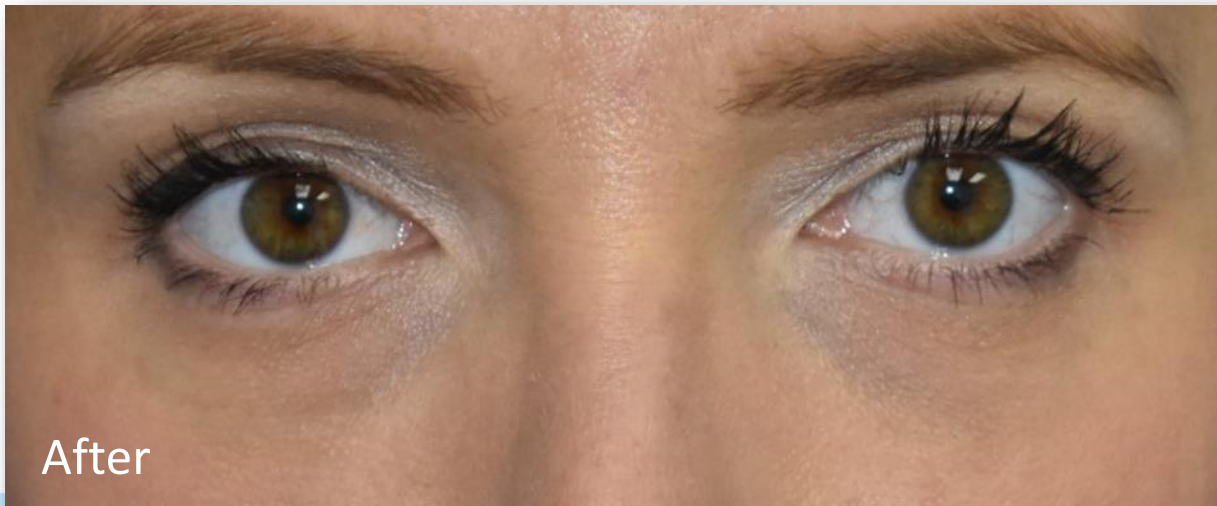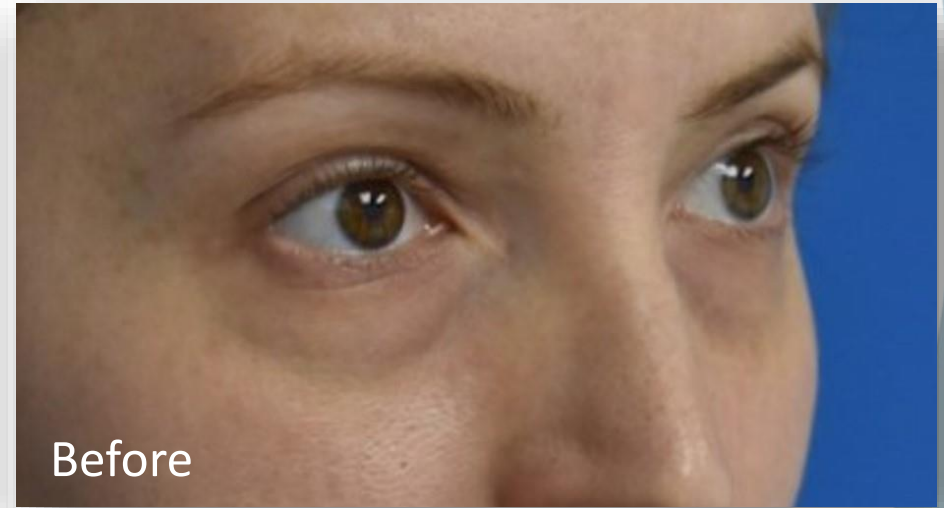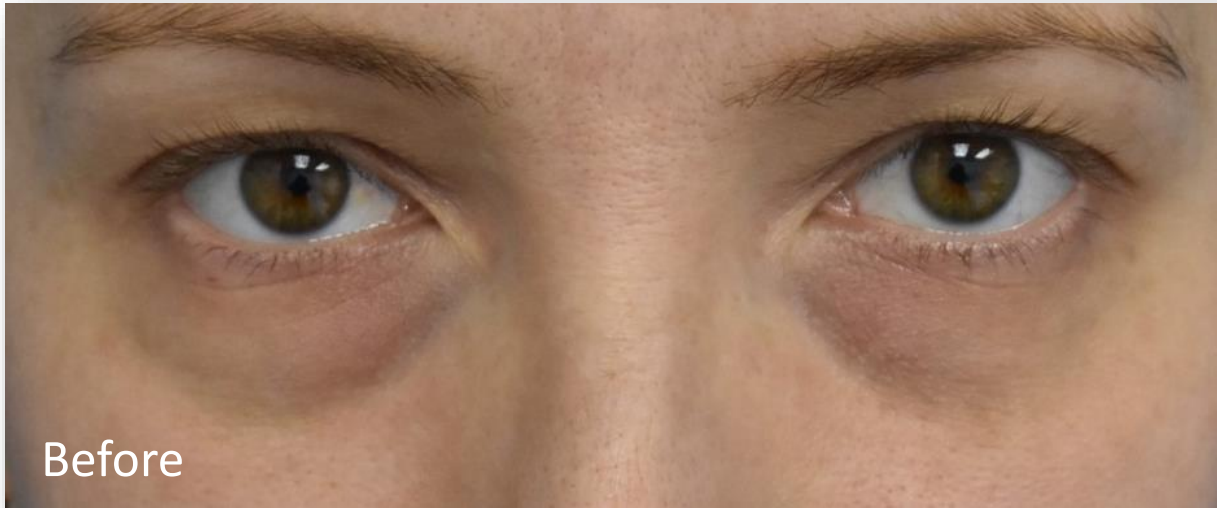*Private Practice*

*University of Chicago*

*University of Illinois*



# Example: Belotero Balance 0.4 mL per side



# Patient Analysis & Selection

## Patient concern

- Eye bags
- Tired appearance
- Dark circles

## Cause of “dark circles”

- Pigment (brown)
- Vascular (blueish purple)
- Shadow of prominent fat

## Extent of fat herniation

## Malar support (vector)

## Idea Patient

- Young
- Matching lid skin color
- Minimal fat herniation
- Good skin

## Not Idea Patient

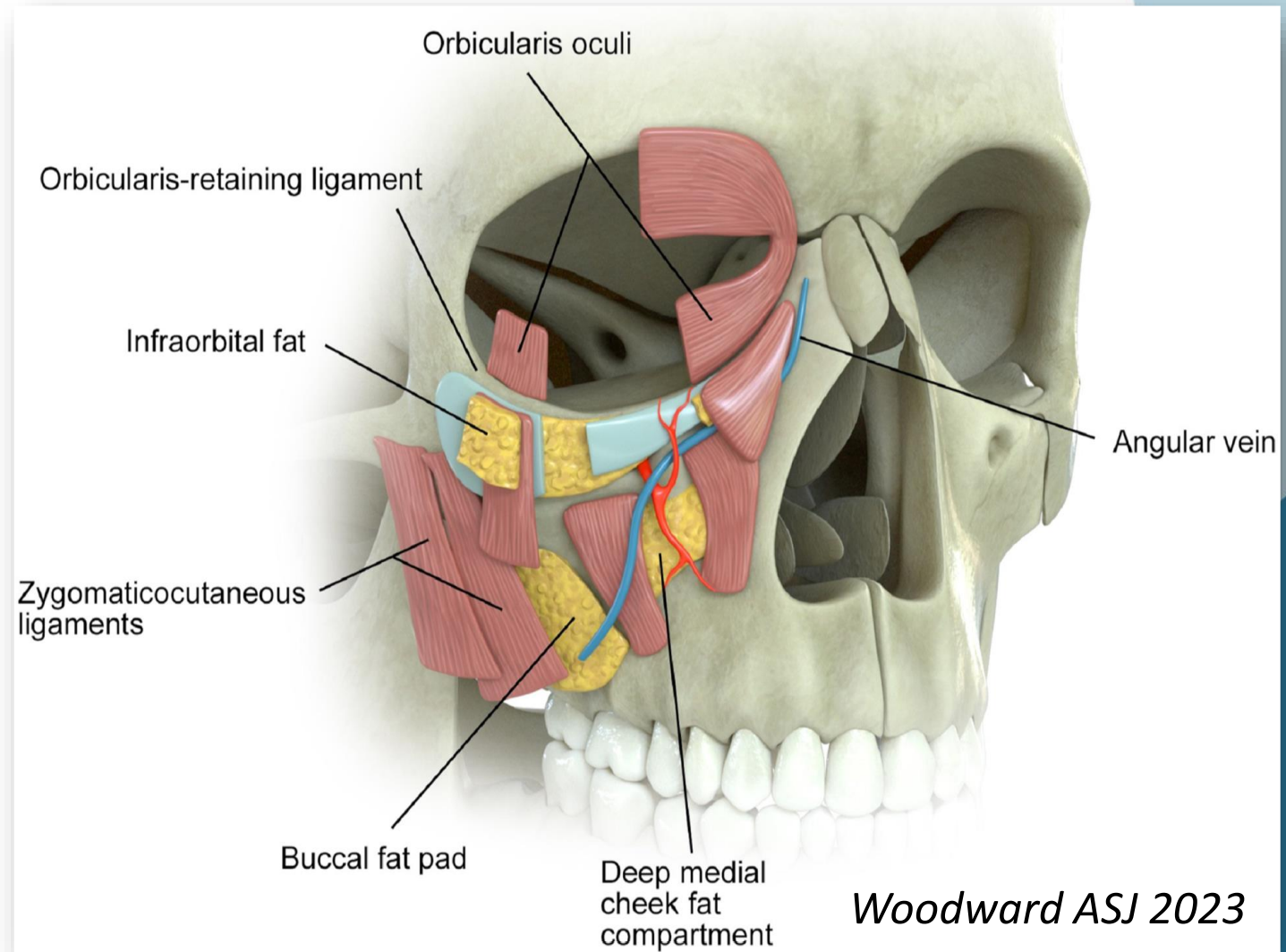
- Older
- Skin discoloration
- Excessive fat herniation
- Poor malar support
- Lax & thin skin





# Anatomy: Overcomplicated & Oversimplified

- More vascular
- Few useful landmarks
- Feel cannula tip
- Inject
  - Deep to orbicularis muscle
    - No easy plane above muscle
  - On periosteum
    - Less important medially
    - More important laterally
    - Easier with 31G Needle



# Preparation

## Patient Expectations

- Goal is 70%-80% correction
- No more than 0.5 mL/side first time
  - Can add more filler 2-4 weeks later
- Combined treatments
  - Laser
  - Neuromodulator
- Possibility of edema
- Hyaluronidase reversal

## Patient comfort is critical

- Minimizes movement

# Preferred Products

Use hyaluronic acid (HA) products

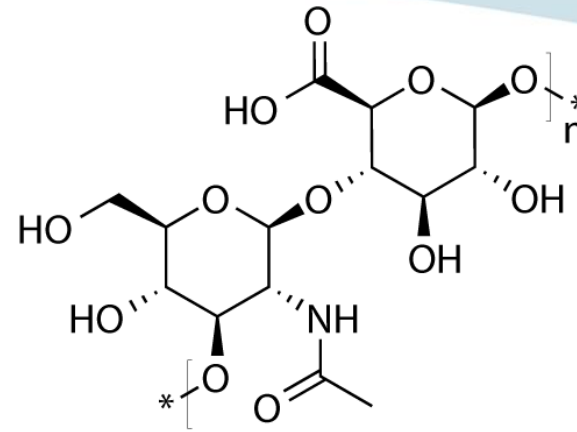
- Can be reversed

## FDA Approved for Infraorbital Hollows

- Belotero Balance (HA) **Preferred**
  - Less Tyndall effect?
- Restylane Eyelight (HA)
- Volbella (HA)

## NOT FDA Approved for Infraorbital Hollows

- Versa (HA)



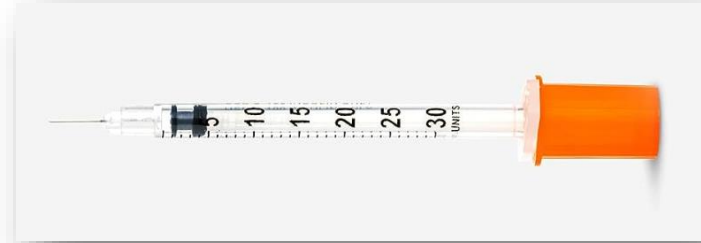

# Preferred Products

## Injection Cannula

- 27G (or 25G) x 1.5 inch

## Injection Needle

- 31G on 0.3 mL insulin syringe



## Anesthetic

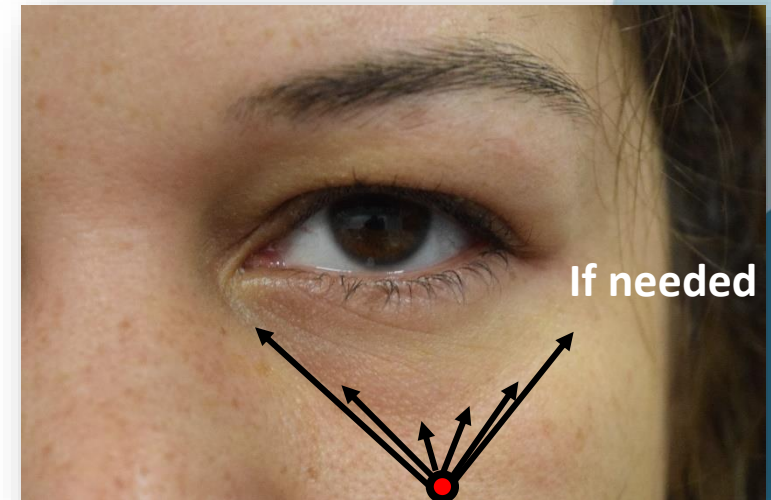
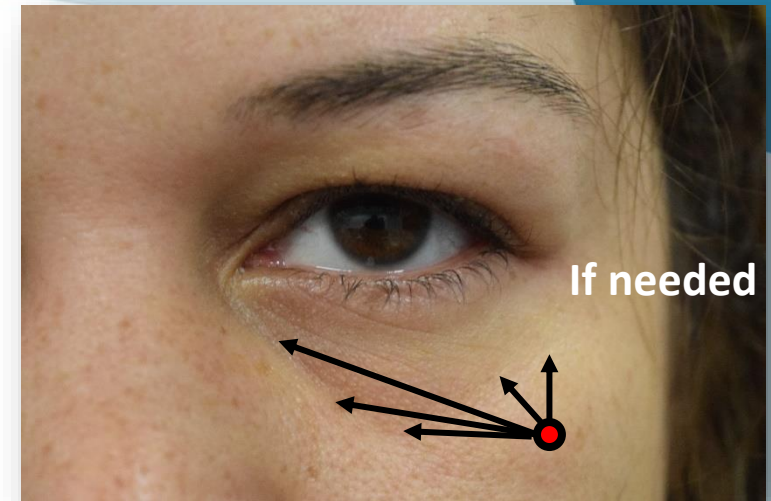

- 0.15 mL 2% lidocaine + epinephrine at cannula insertion sites
- Topical anesthetic 23% Lidocaine + 7% Tetracaine x 20 minutes
- Vibration distraction



# Injection Technique

## Cannula

- Insert cannula from lateral or inferior approach
  - “Deep” but not need to be on periosteum
- Tent cannula up to see tip
- Stop before medial canthus
- Retrograde injection on cannula withdrawal
  - $\leq 0.05$  mL per pass
- Gentle fingertip massage for any lumps

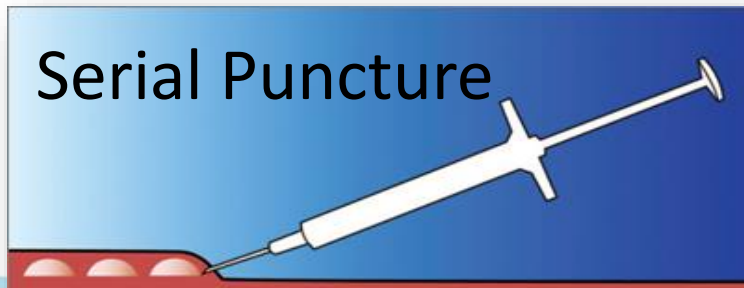
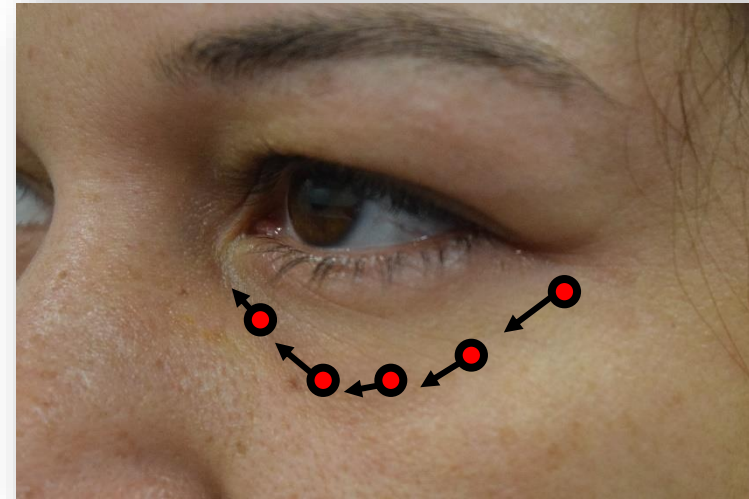
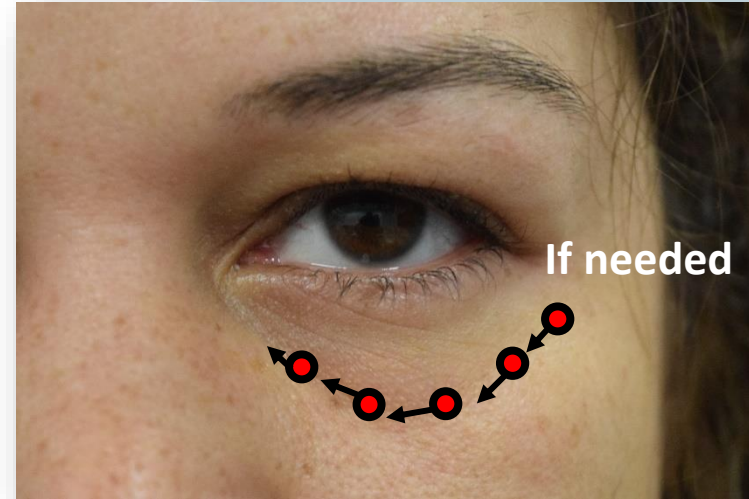




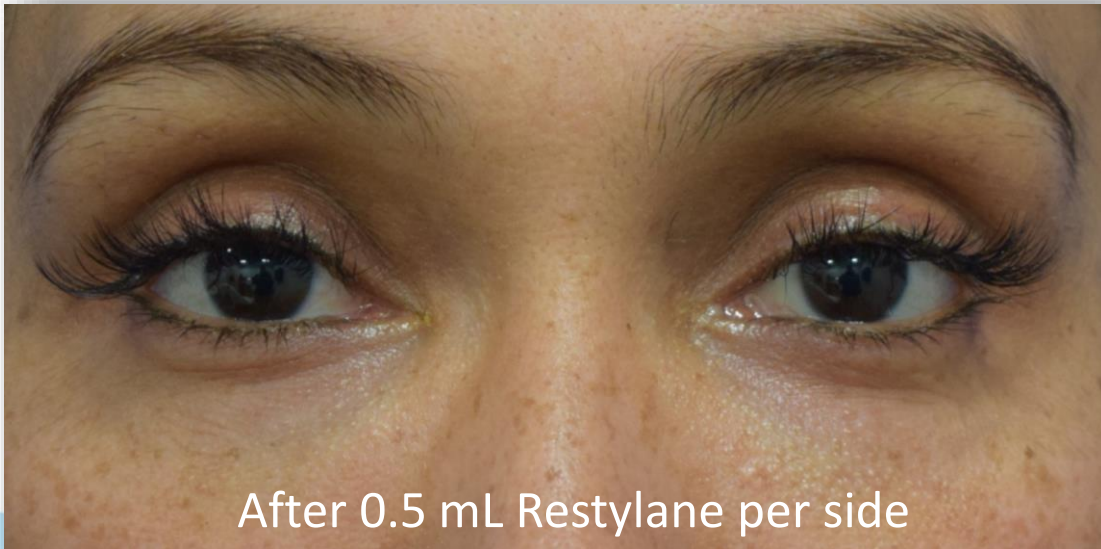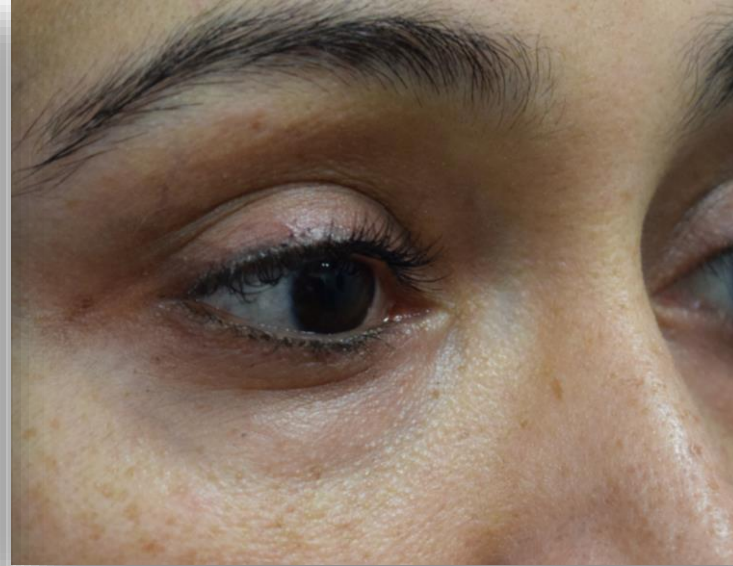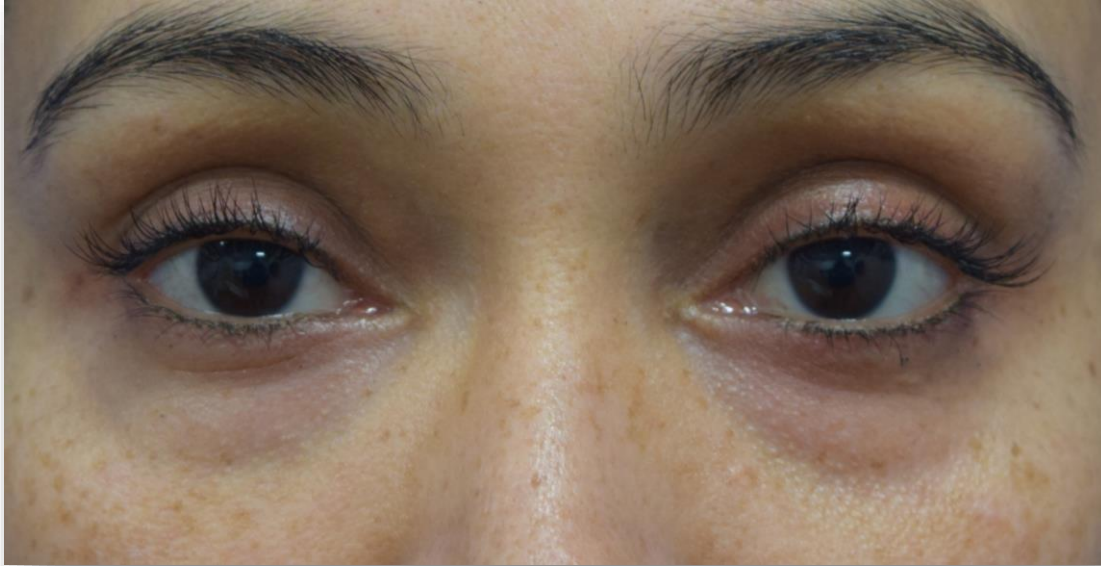# Injection Technique

## 31G Needle

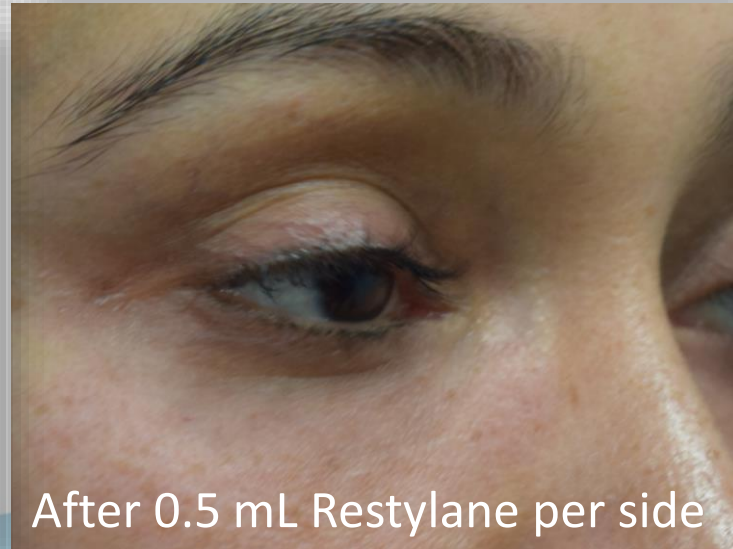- Medial to lateral
- Insert perpendicular to orbital rim
- Stop at periosteum
- Inject 0.01 ml to 0.02 per site
- Move needle medial & lateral for more injections
- Insert at new site laterally
- Gentle fingertip massage for lumps



# Clinical Example



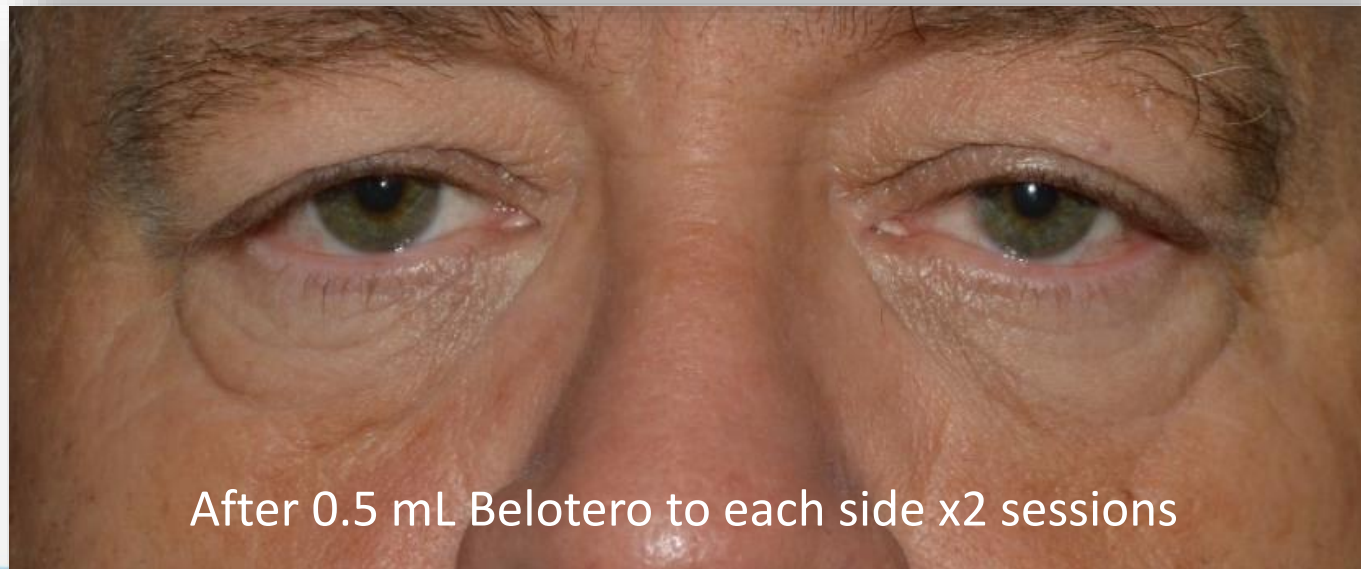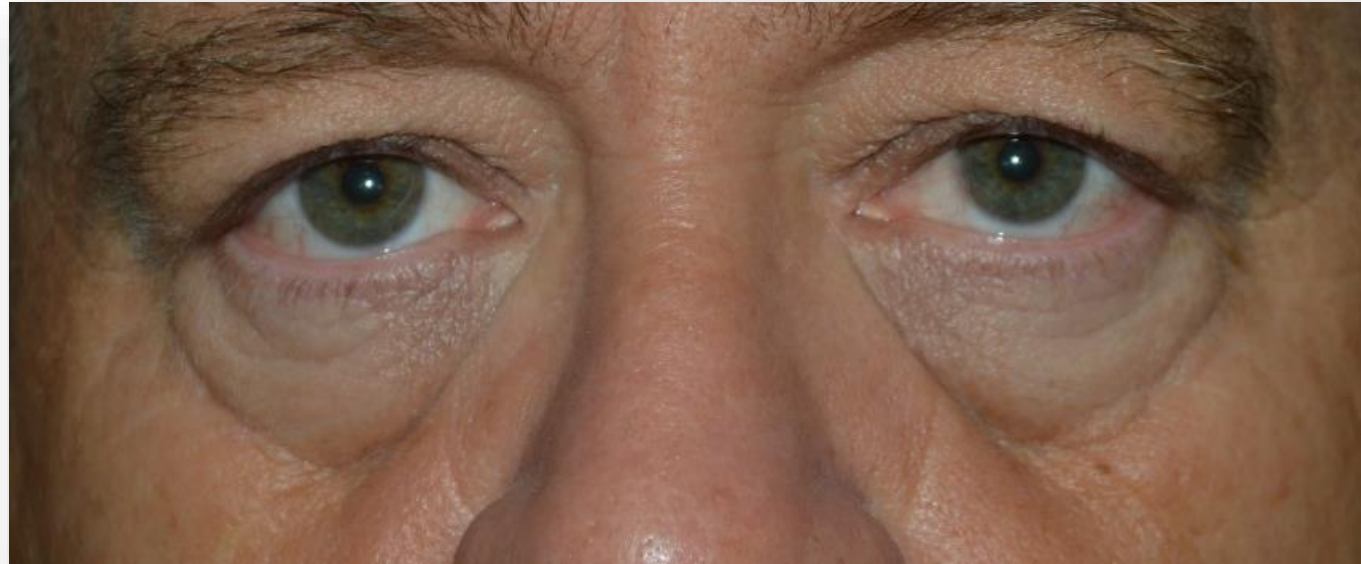After 0.5 mL Restylane per side



After 0.5 mL Restylane per side

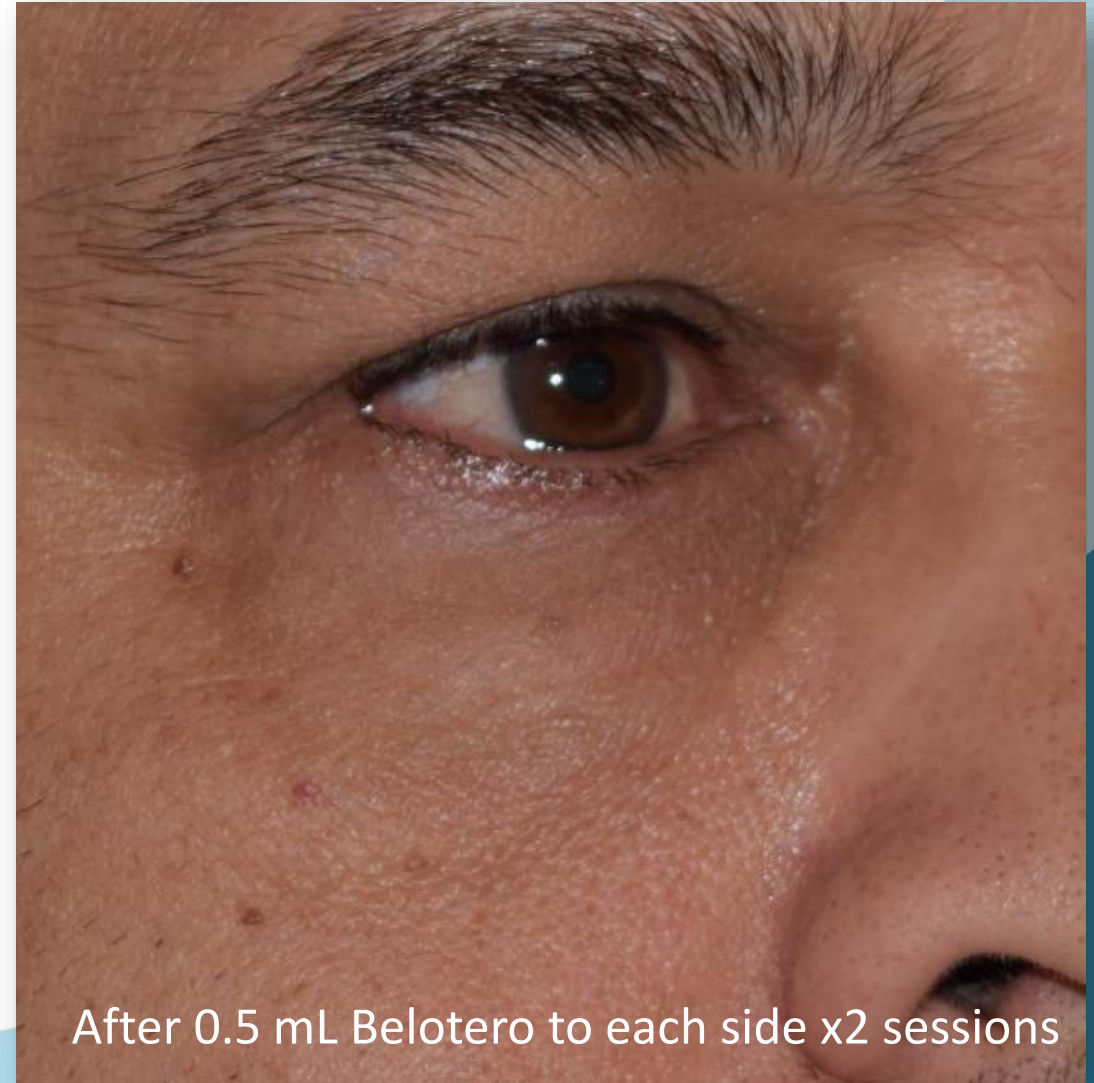
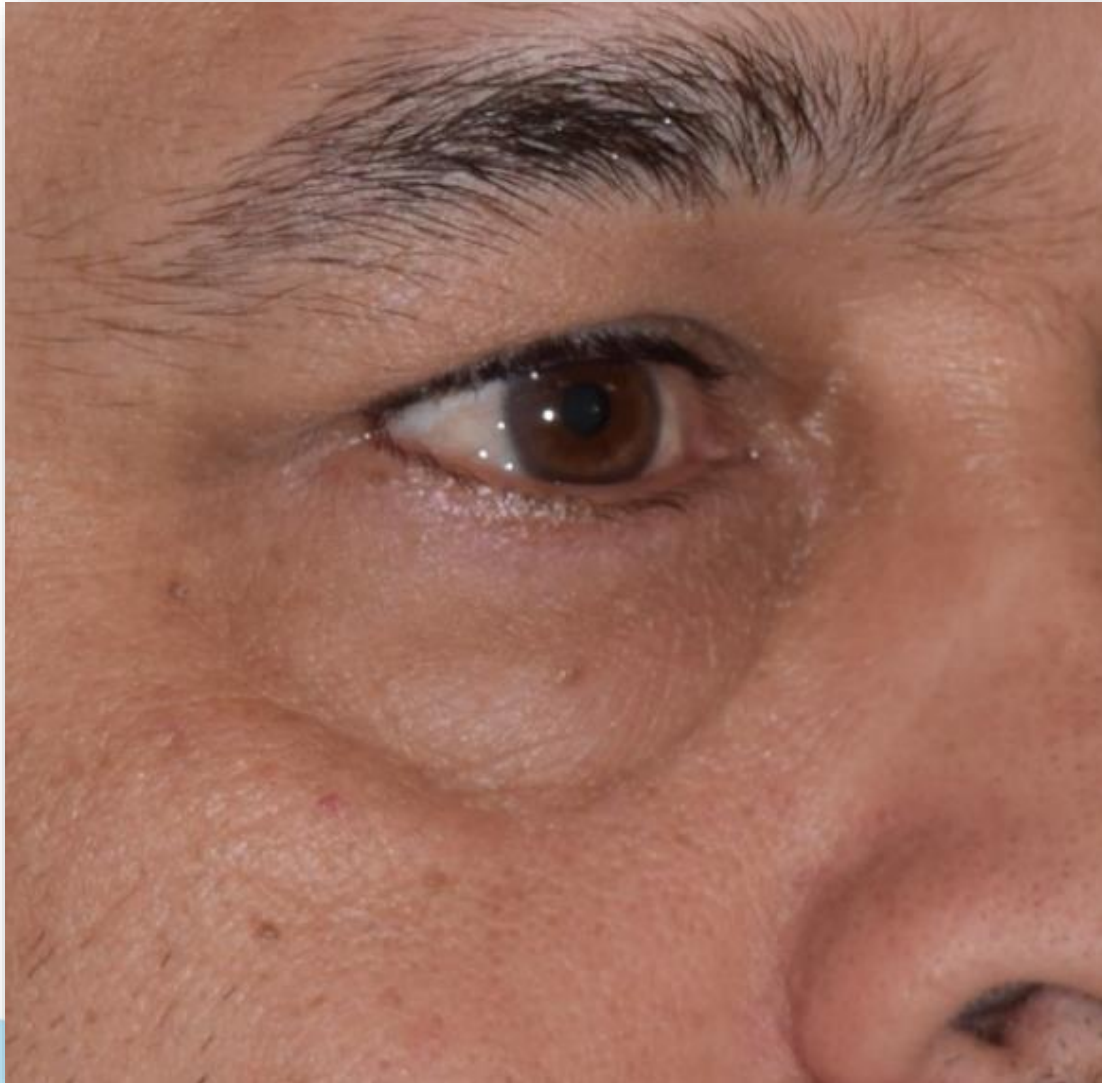

# Clinical Example: Declined Surgery & CO<sub>2</sub> Laser



After 0.5 mL Belotero to each side x2 sessions

# Clinical Example: Declined Surgery



After 0.5 mL Belotero to each side x2 sessions

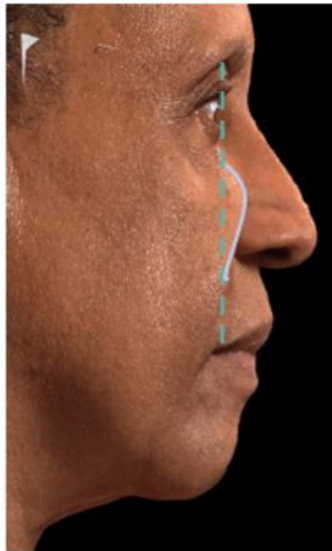

# Need to Assess Midface Support & Volume

## Assess the Facial Vector to Determine Undereye Hollows Treatment Plan

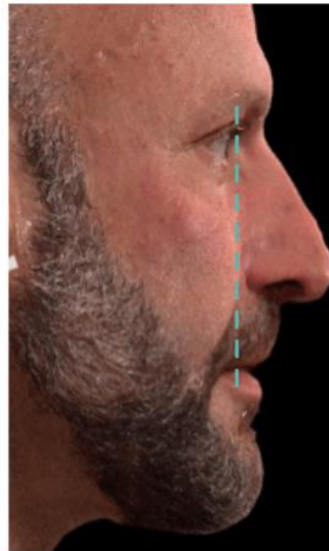
Assess the vector between the anterior corneal surface and the malar eminence

If a patient has a negative vector, you must first fill the mid-cheek



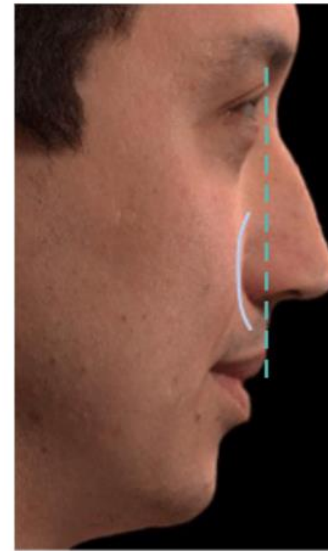
**Positive Vector**

Cheek mass lies anterior to the cornea



**Neutral Vector**

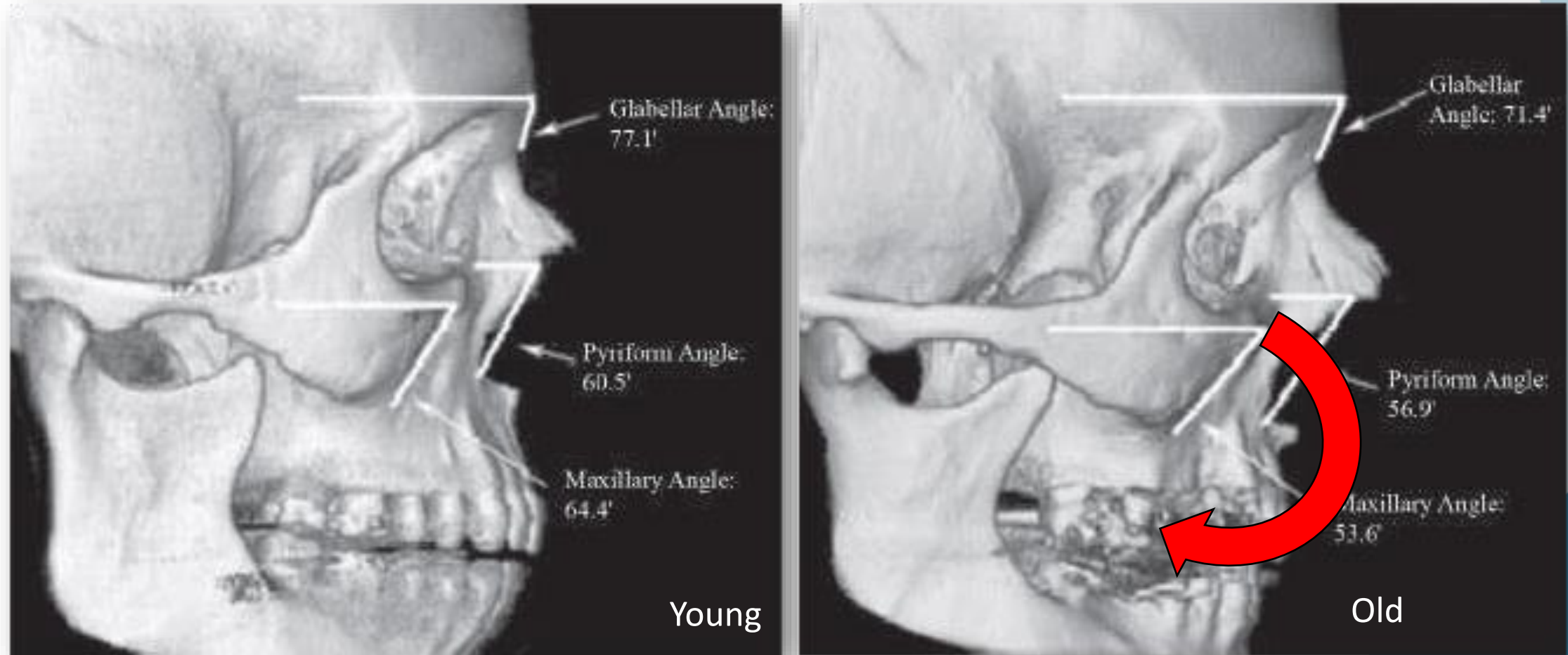
Cheek mass lies in the same plane as the cornea



**Negative Vector**

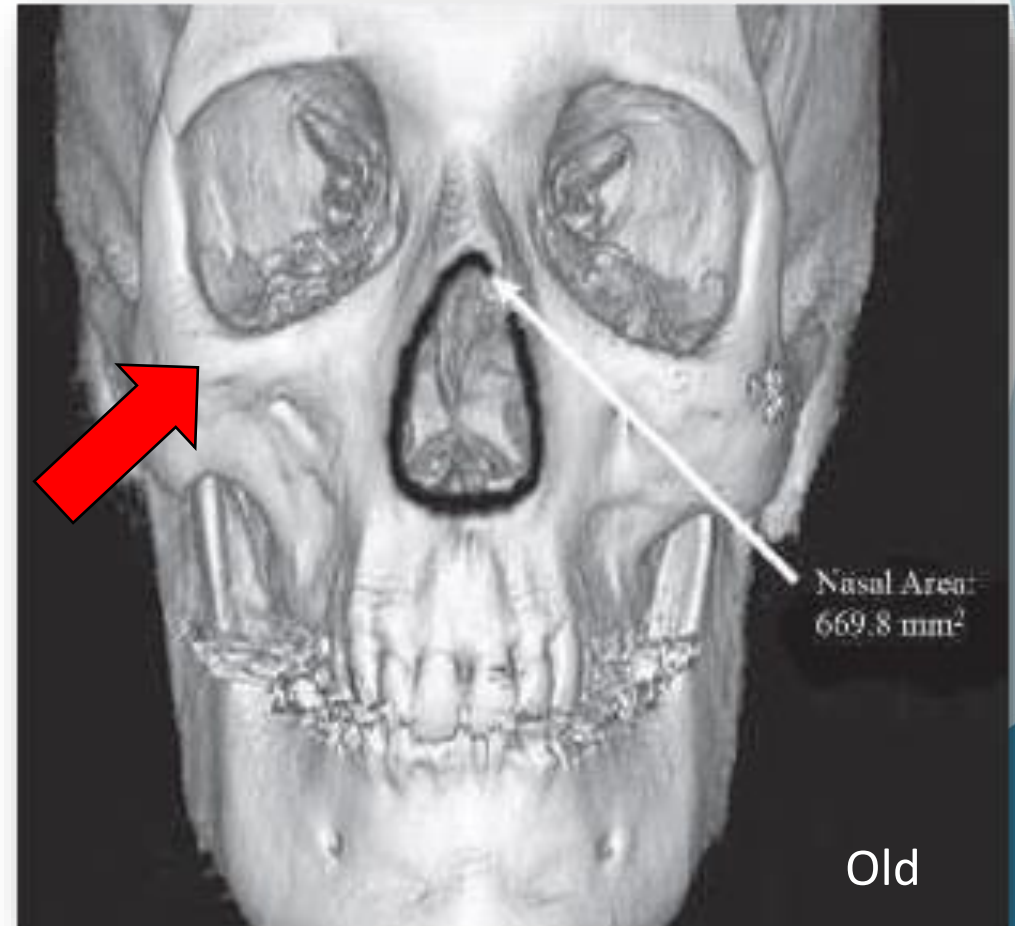
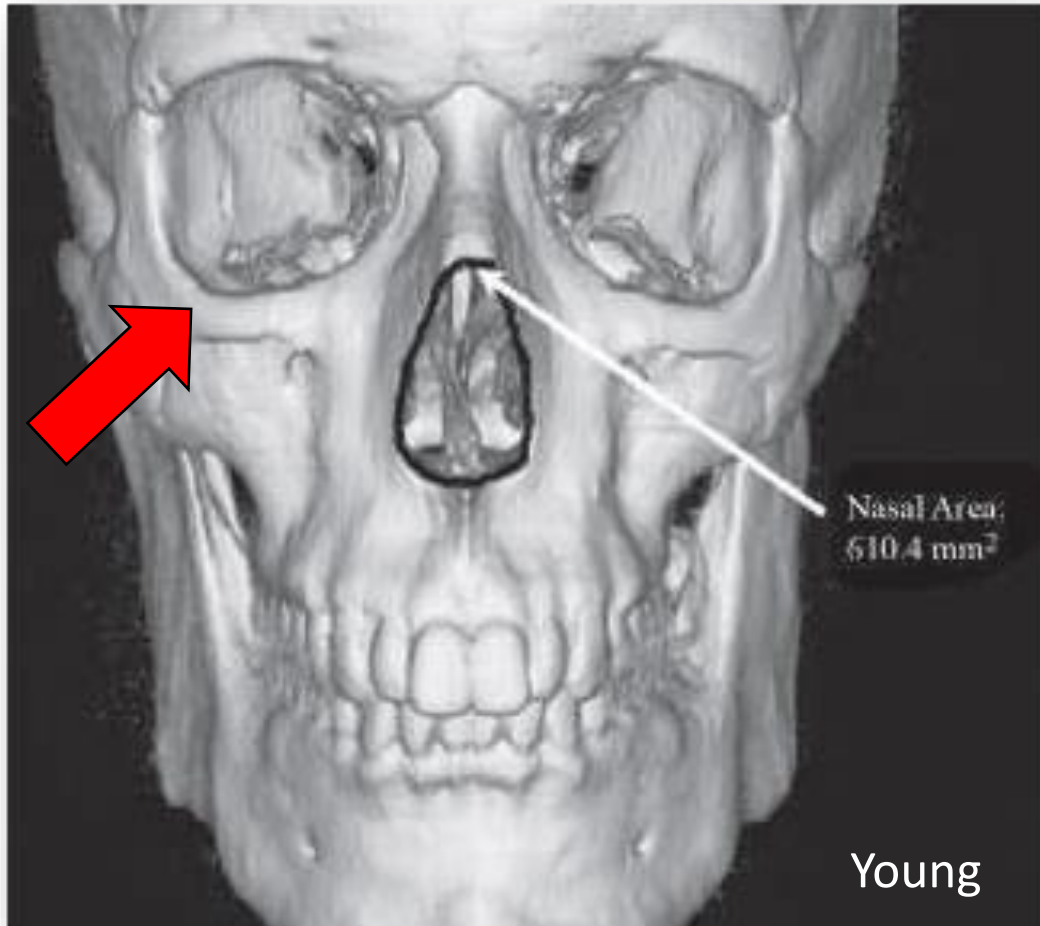
Cheek mass lies posterior to the cornea

# Aging Facial Bone Changes



Bones in midface & jaw become less prominent causing loss of structural support resulting in sunken appearance

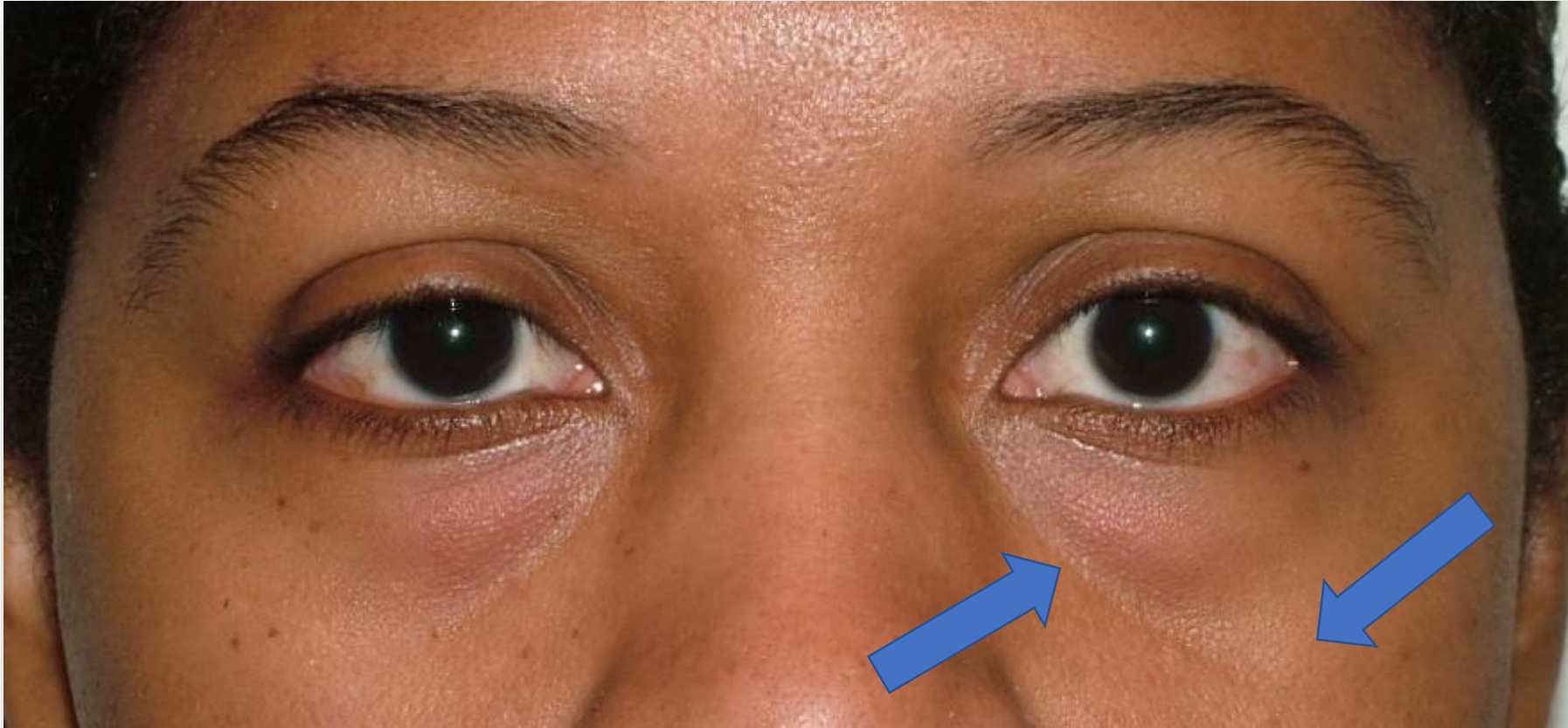# Aging Facial Bone Changes



Orbits become larger causing loss of structural support leading to aged appearance

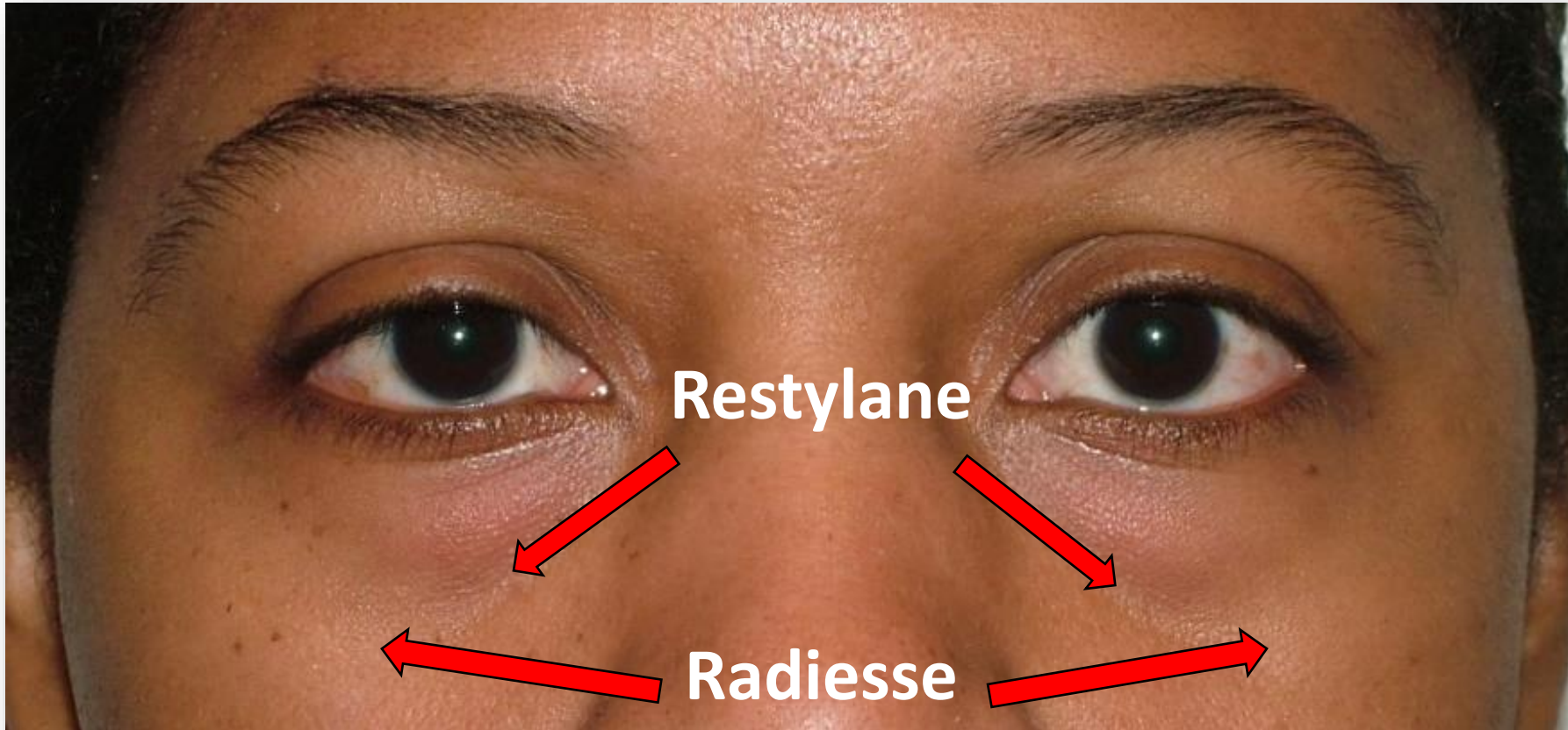


# Infraorbital Hollow with Poor Malar Support

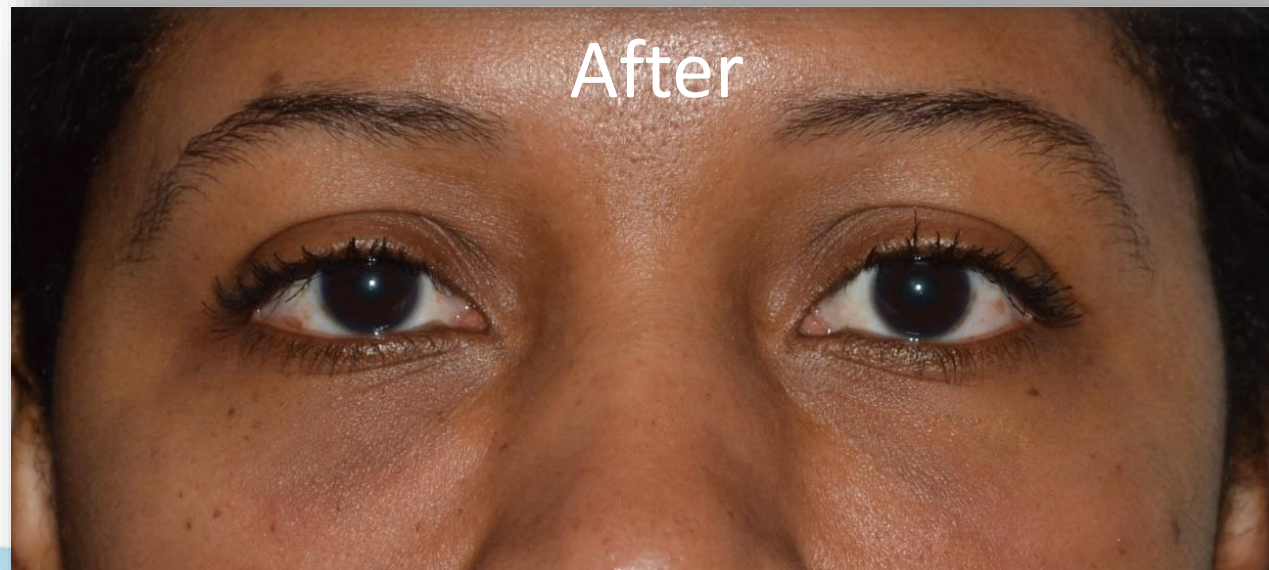
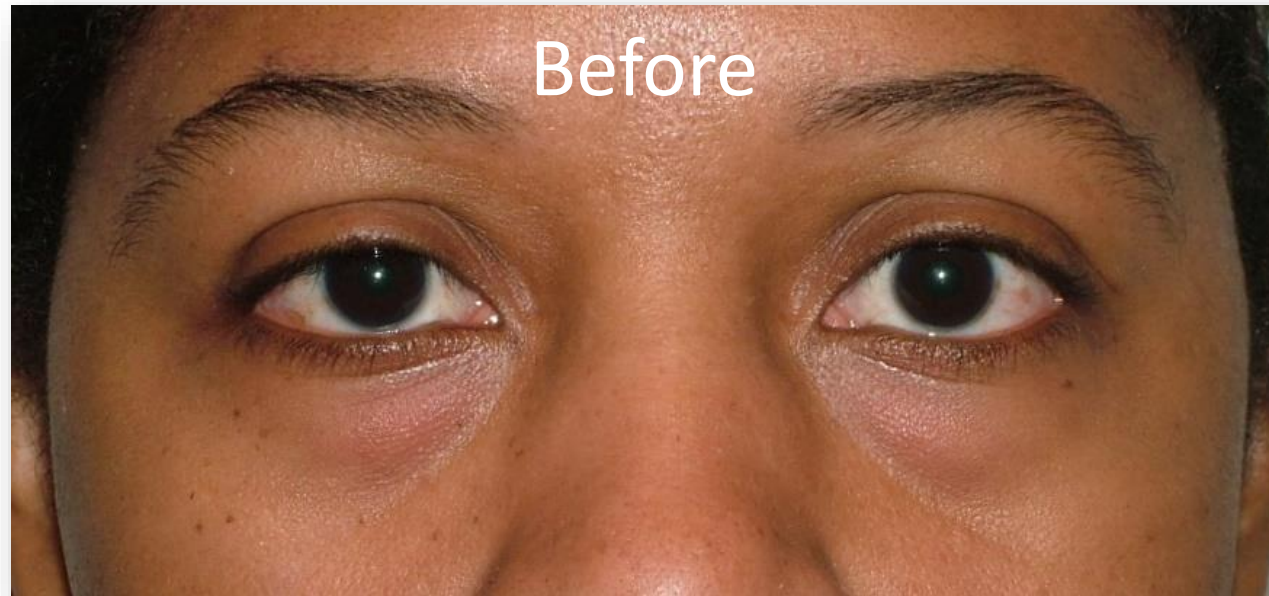


# Treat the Upper Cheek, then Infraorbital

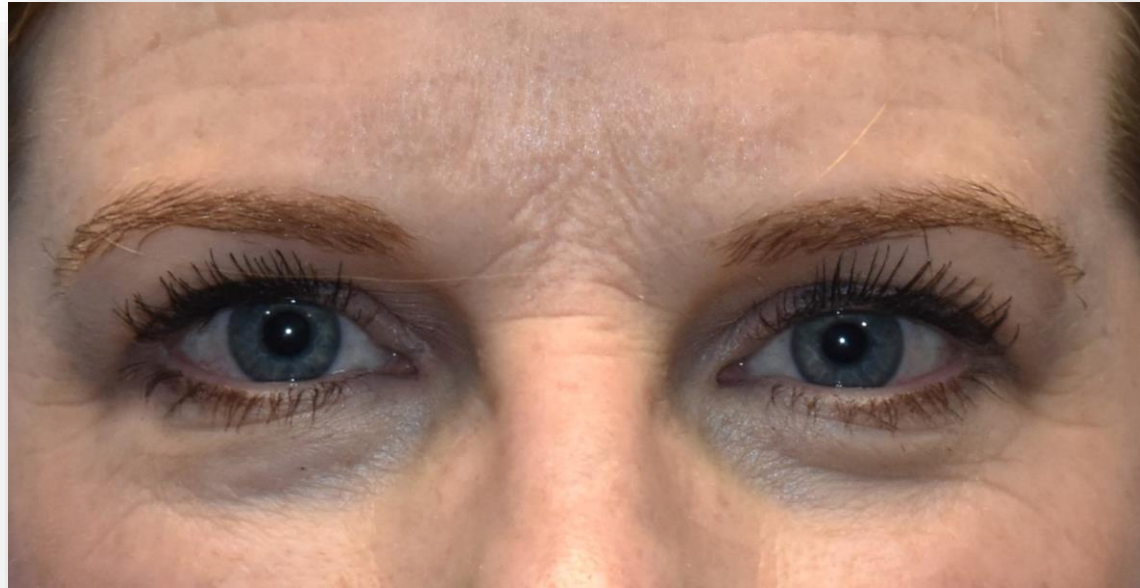

# Balanced Midface

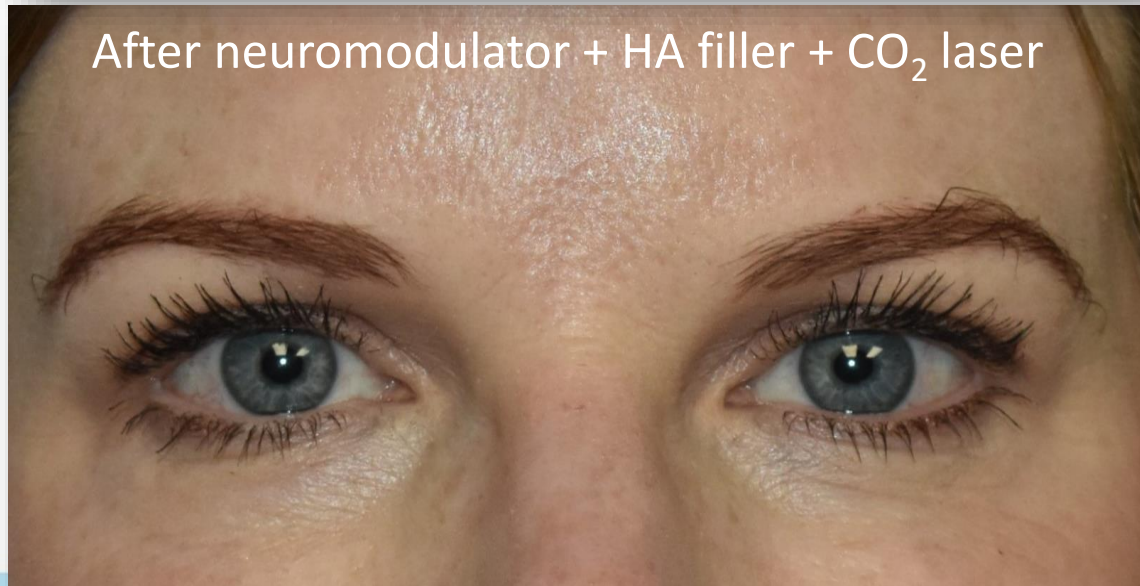



# Relax + Refill + Resurface



After neuromodulator + HA filler + CO<sub>2</sub> laser



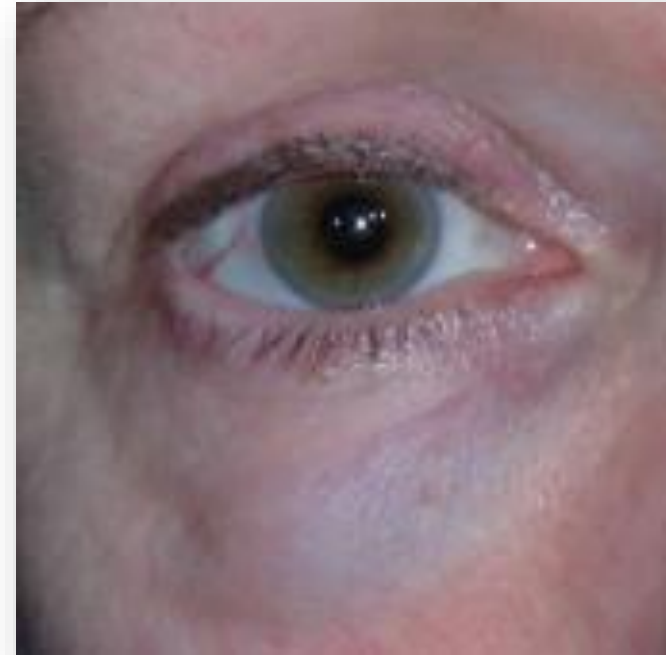
# Risks & Complications

## Tyndall Effect

Bluish hue within the skin after HA injection

- Too superficial placement
- Too much injected
- Bolus injections
- Thin skin

**Treatment: Dissolve with Hyaluronidase if not responsive to massage after 2-4 weeks**





# Risks & Complications

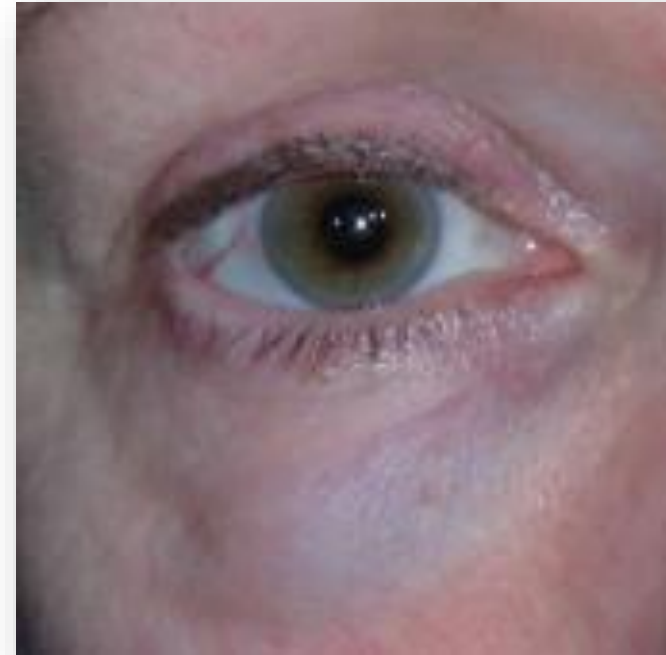
## Persistent Edema

Puffy lower lids

May appear months or years later

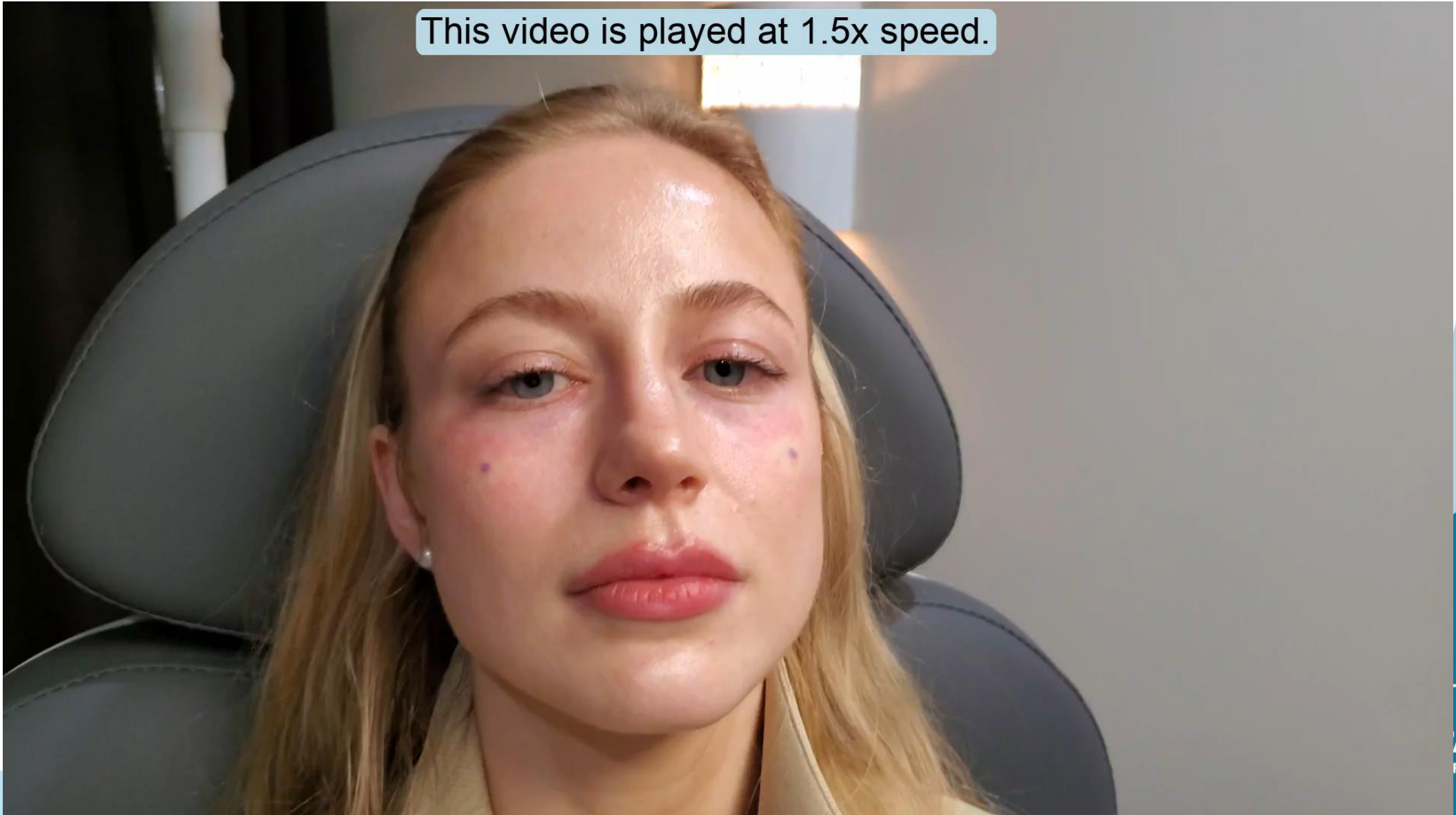
- Too superficial placement
- Too much injected
- Bolus injections
- Lymphatic obstruction

**Treatment: Dissolve with Hyaluronidase if not responsive to massage after 2-4 weeks**

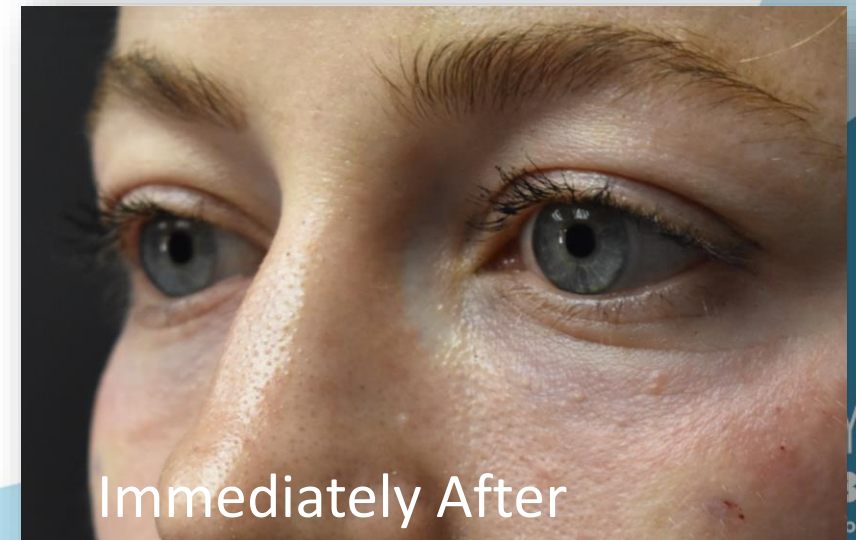
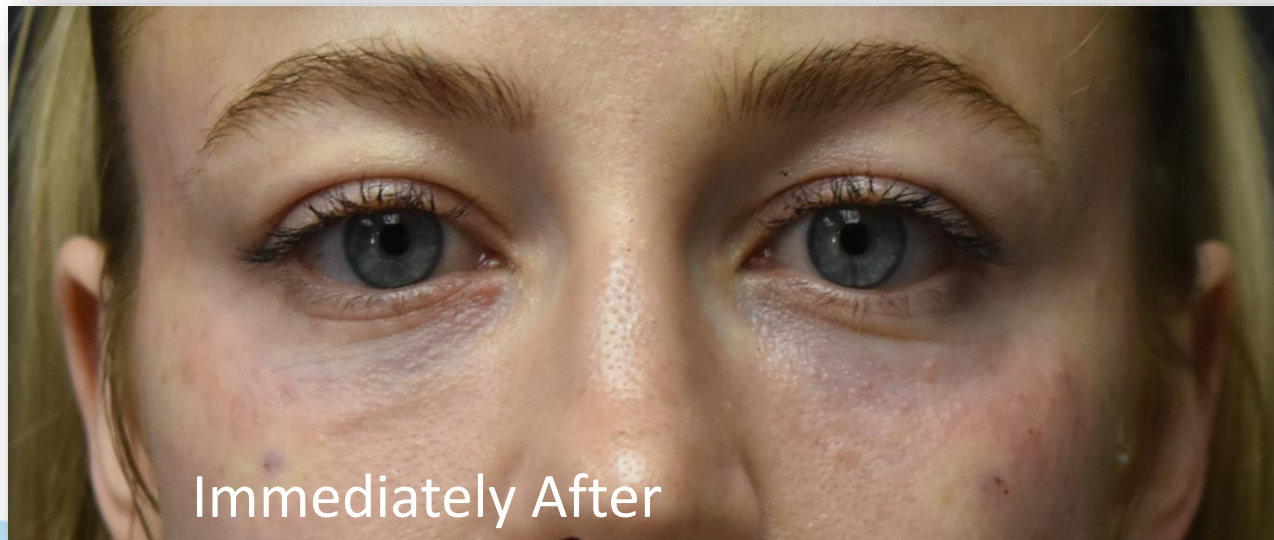
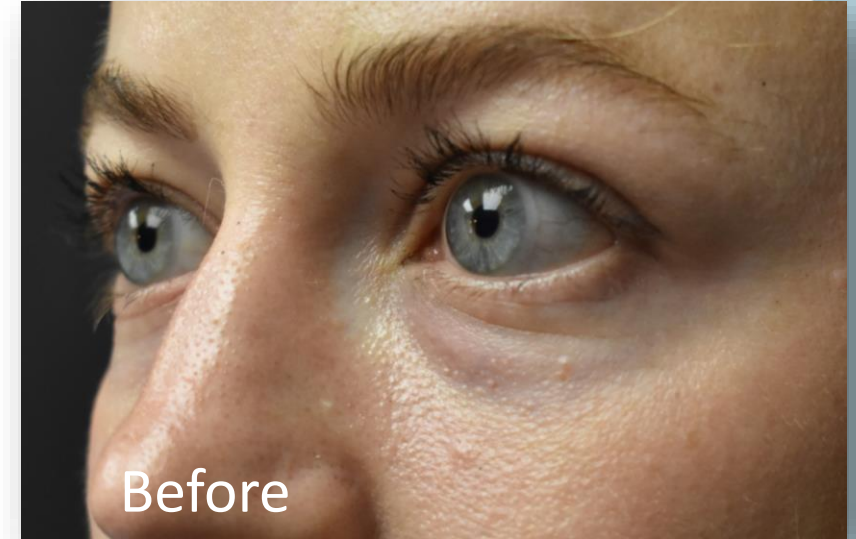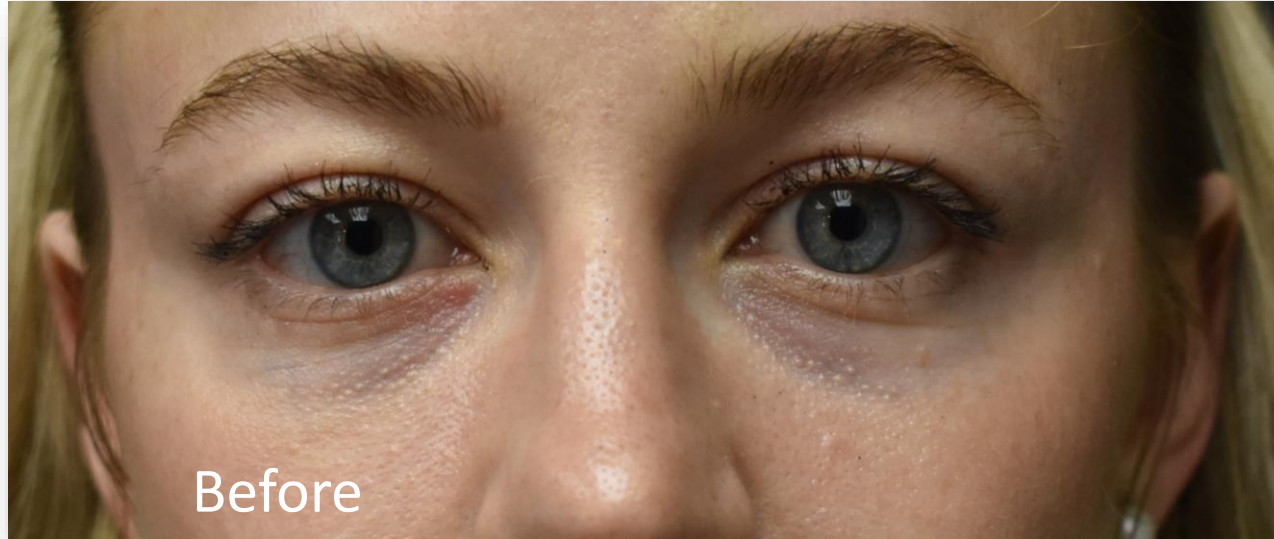# Injection Example: Video Demonstration

This video is played at 1.5x speed.





# Injection Example: 0.8 mL Belotero Balance





# Injection Example: 0.8 mL Belotero Balance





# THE ARTISTRY OF **INJECTABLES**

Comprehensive Training For Your Practice

## Correction of Infraorbital Hollows

Karol A Gutowski, MD, FACS

Questions?

[Karol@DrGutowski.com](mailto:Karol@DrGutowski.com)

