

Neck Laser Assisted Liposuction: Lessons Learned

Karol A Gutowski, MD, FACS

Private Practice

University of Chicago

University of Illinois - Chicago

26th State-of-the-Art in Facial
Aesthetics

Jung Hotel,
New Orleans, LA
March 28-31, 2019

Disclosures

Merz – Advisory Board & Training Site

Syneron/Candela – Training Site

NO financial interests in any company in this presentation

Will use device brand names due to lack of distinguishing generic names

Submental Liposuction: SAL & LAL

Cosmetic

Submental Suction-Assisted Lipectomy without Platysmaplasty: Pushing the (Skin) Envelope to Avoid a Face Lift for Unsuitable Candidates

Joe M. Gryskiewicz, M.D.

Minneapolis, Minn.

Supplement

Prediction of Treatment Outcomes for Neck Rejuvenation Utilizing a Unique Classification System of Treatment Approach Using a 1440-nm Side-Firing Laser

Gabriella A. DiBernardo, BS; and Barry E. DiBernardo, MD

Aesthetic Surgery Journal
2018, Vol 38(S2) S43–S51
© 2018 The American Society for
Aesthetic Plastic Surgery, Inc.
Reprints and permission:
journals.permissions@oup.com
DOI: 10.1093/asj/sjy066
www.aestheticsurgeryjournal.com

OXFORD
UNIVERSITY PRESS

Neck Rejuvenation: More Options

Plast Reconstr Surg 2006

SPECIAL TOPIC 

Neck Rejuvenation Revisited

Rod J. Rohrich, M.D.
Jose L. Rios, M.D.
Paul D. Smith, M.D.
Karol A. Gutowski, M.D.

*Dallas, Texas; Tampa, Fla.; and
Madison, Wis.*

Purpose: Restoration of the aesthetic neck contour is an integral component of facial rejuvenation. Multiple deformities of the neck and chin complex can make treatment of the cervical region daunting. An algorithmic approach to neck rejuvenation based on individual anatomic and clinical analysis is prudent. The authors created a simplified anatomic approach to the most common cervical deformities encountered in the patient seeking facial rejuvenation.

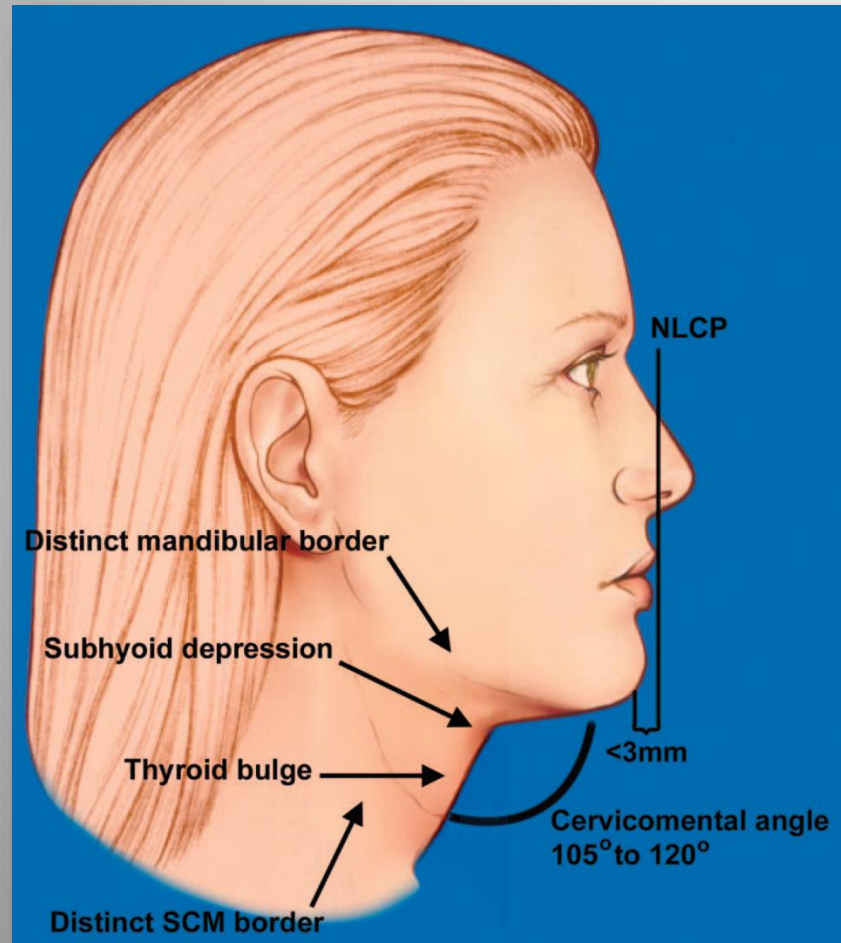
- Liposuction (SAL or UAL)
- Chin Implant
- Neuromodulator
- Neck +/- Face Lift

Options

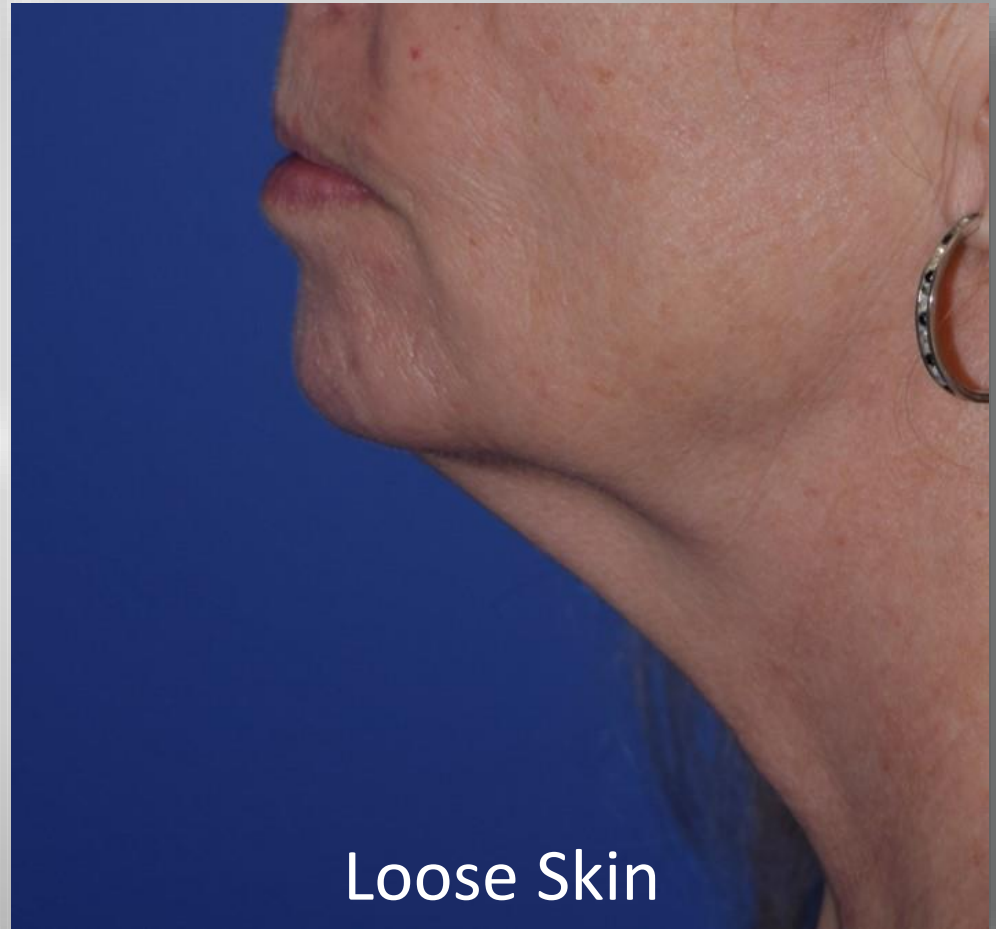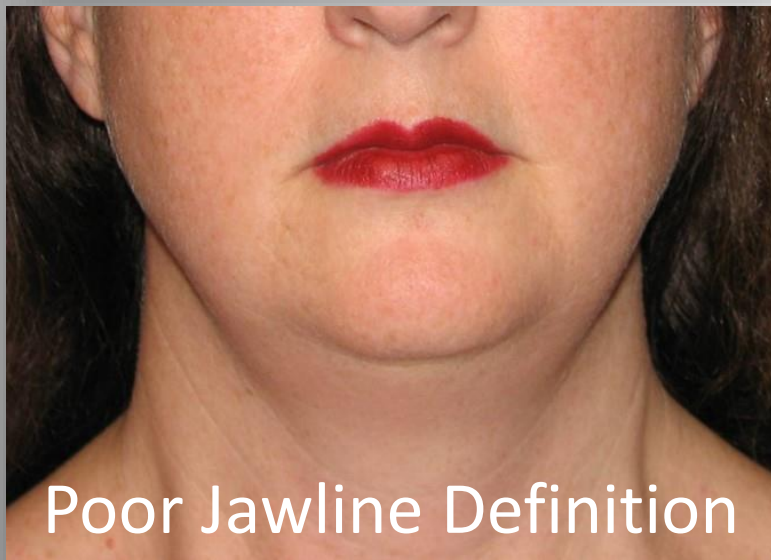
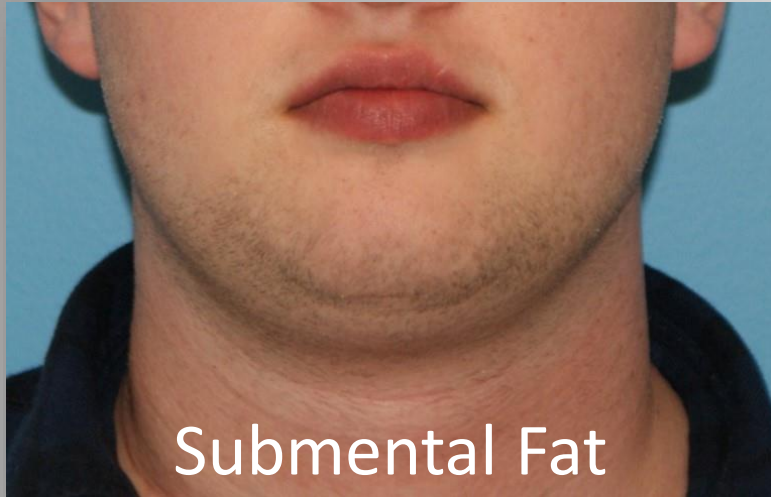
- External Energy Devices
 - Radio Frequency (many)
 - Micro Focused Ultrasound (Ulthera)
- Cryolipolysis (CoolSculpting)
- Neuromodulators (for platysmal bands)
- Percutaneous Collagen Induction (Micro Needling)
- Injection Lipolysis (Kybella)
- Thermi RF
- RF Microneedling
- Liposuction
 - Laser Assisted Liposuction
 - RF Assisted Liposuction
- Suture lifts
- Chin implant
- Fillers

Ideal Neck

Over stylized & not realistic in most patients



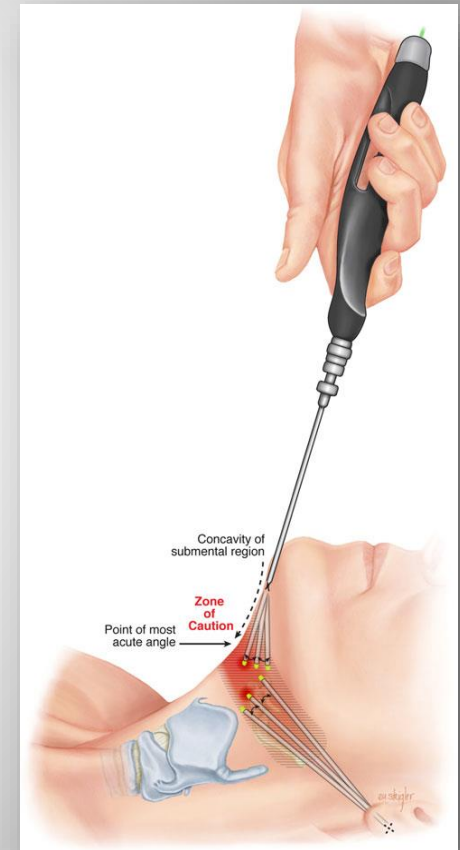
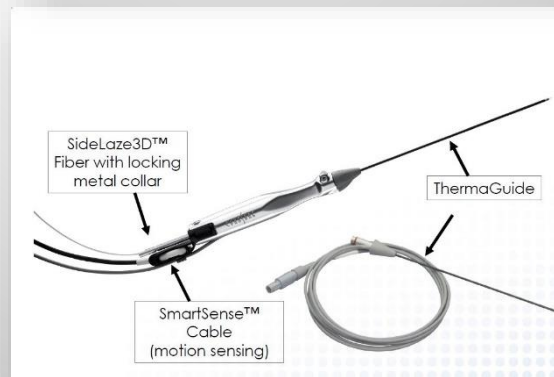
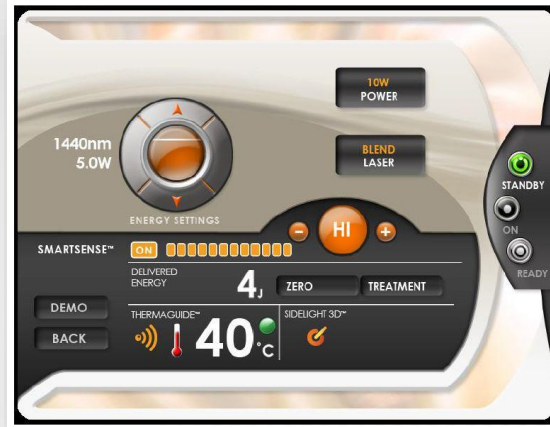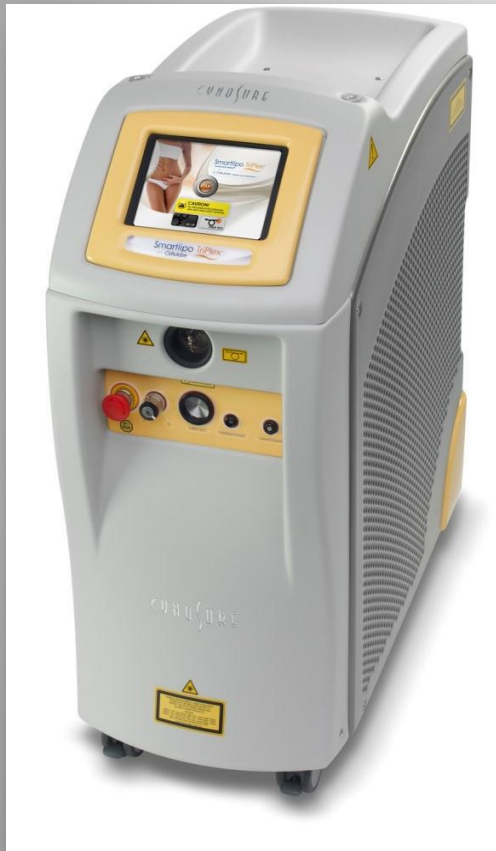Top 3 Issues To Address



Neck Liposuction Personal Experience

- Last 5 years: 230 Cases
- 184 Laser Assisted (LAL)
 - All awake
 - Consider for ≥ 30 yr old
- 46 Traditional (SAL)
 - 31 awake
 - 15 with anesthesia with other procedures
 - Consider for ≤ 40 yr old

1440 nm Side Firing Laser

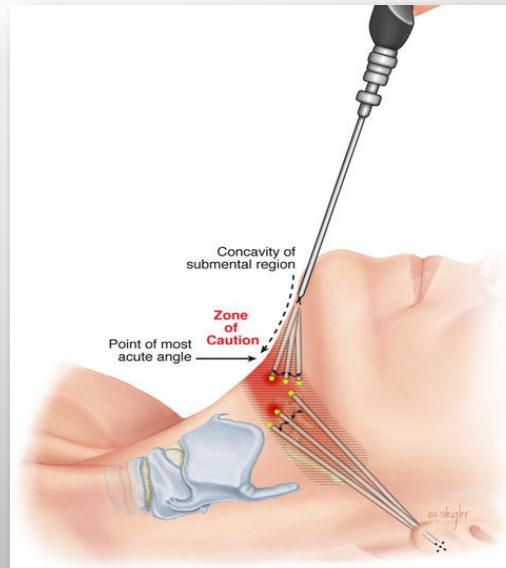
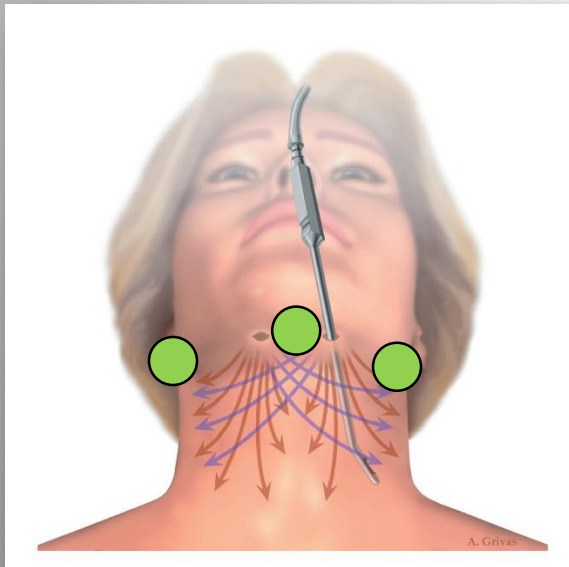


Neck Liposuction Protocol

- No anticoagulants 1 week preop
- Controlled hypertension
- 3 access incisions (rarely 1)
- Tumescant fluid
 - 500 mg Lido + 0.5 mg Epi + 10 mL Bicarb (500 mL NS)
 - 125 ml to 350 mL (firm, not tense), wait 5 min
- Laser fat reduction until loss of resistance
 - Typically 500J to 1000J
 - NOT needed in most cases

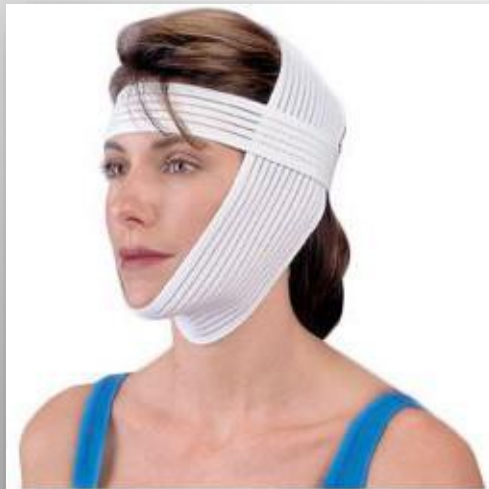Neck Liposuction Protocol

- SAL with 2.7 mm single hole cannula
 - Count cannula passes per side
 - Not just submental, **include the jawline**
 - 50 to 150 mL removed



Neck Liposuction Protocol

- Laser skin tightening to 46°C in 5x5 cm squares
 - Typically 1000J to 3000J
 - Depends on amount of fluid infiltrated
 - Typically 2 passes from different incisions
- Submental compression +/- foam pad



Neck Liposuction Outcomes

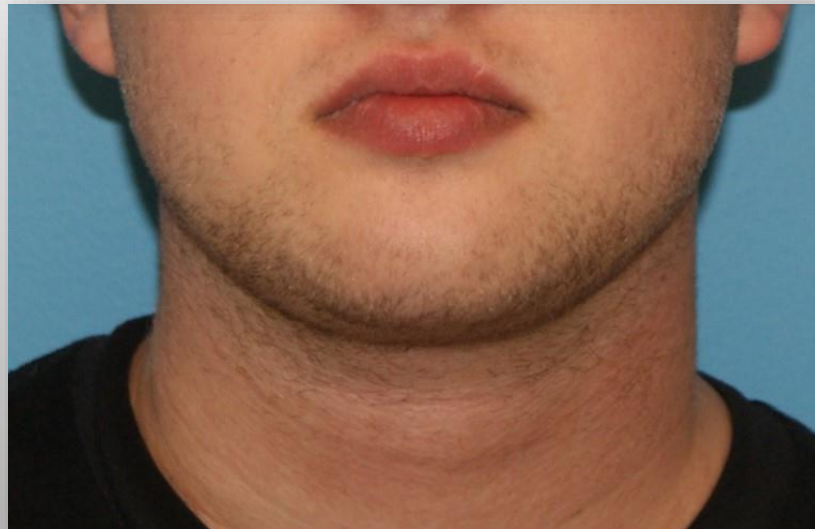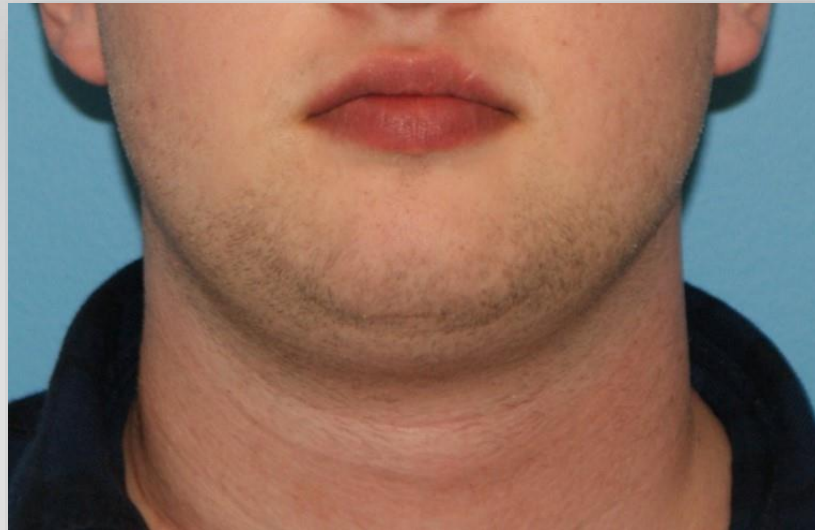• Infection	1
– Folliculitis after 3 wks (Abx + I&D)	
• Bleeding	0
• Significant bruising	1
• Lumps requiring Kenalog injection	18
– LAL	17 (9.2%)
– SAL	1 (2.2%)
• Marginal mandibular weakness	8
– 2 cases lasted 6 to 9 weeks, all resolved	
• Touch up liposuction	5
• Touch up Kybella	1

Neck Liposuction Patient Reported Outcomes

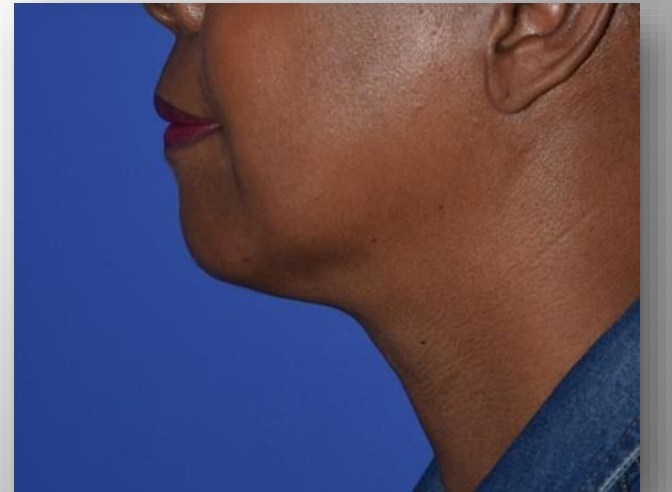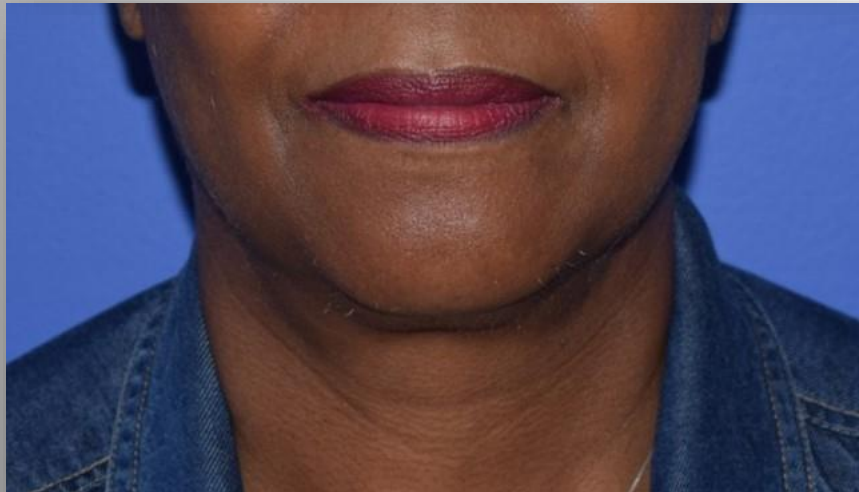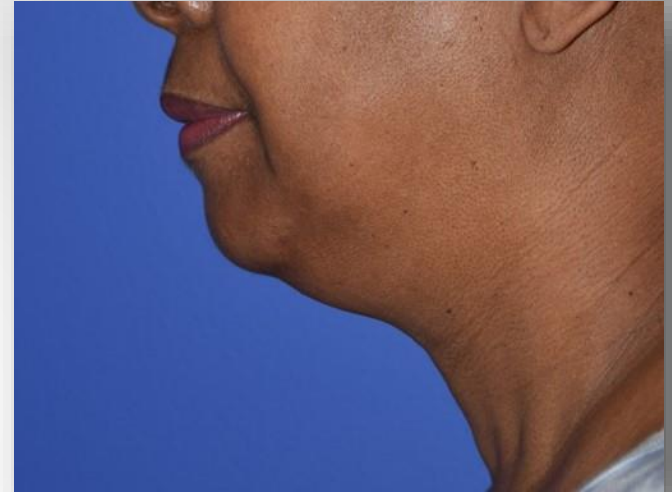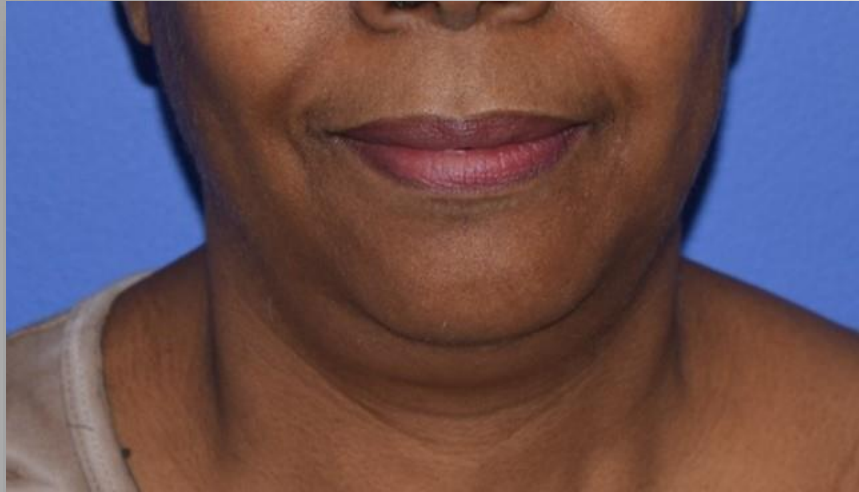Questions for 201 patients after 6 months

- Was it worth it?
 - YES 199
 - MAYBE 2
 - NO 0
- Would you do it again?
 - YES 199
 - MAYBE 1
 - NO 1*
- Satisfied with result?
 - YES 200
 - NO 1*

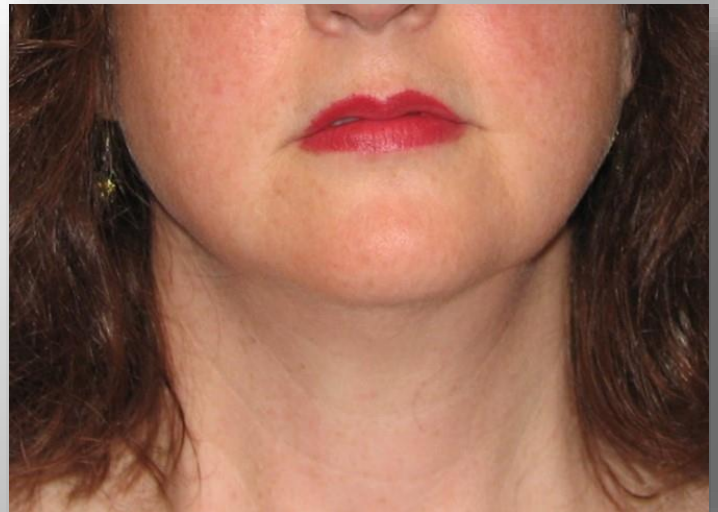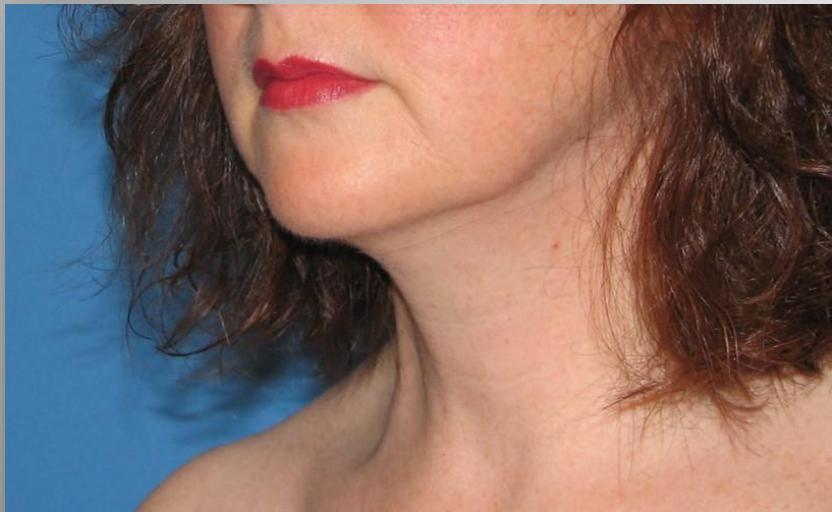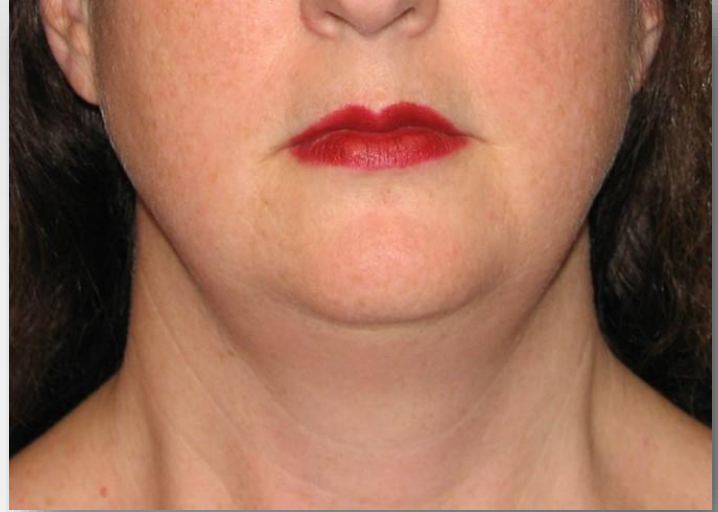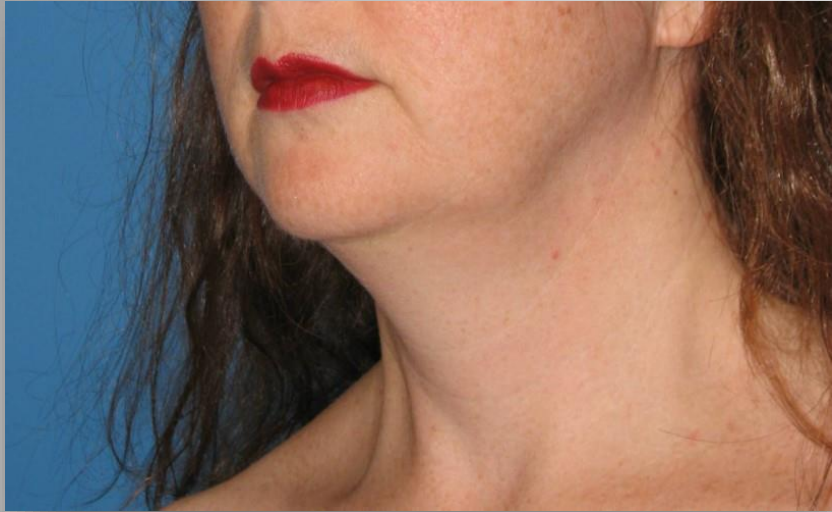Liposuction



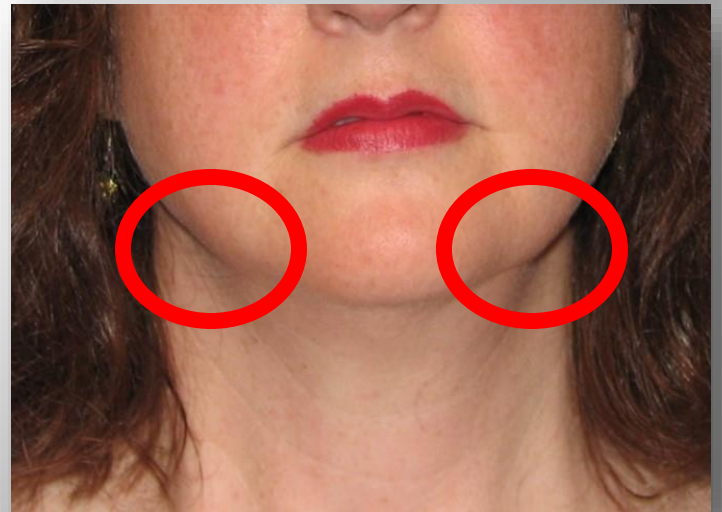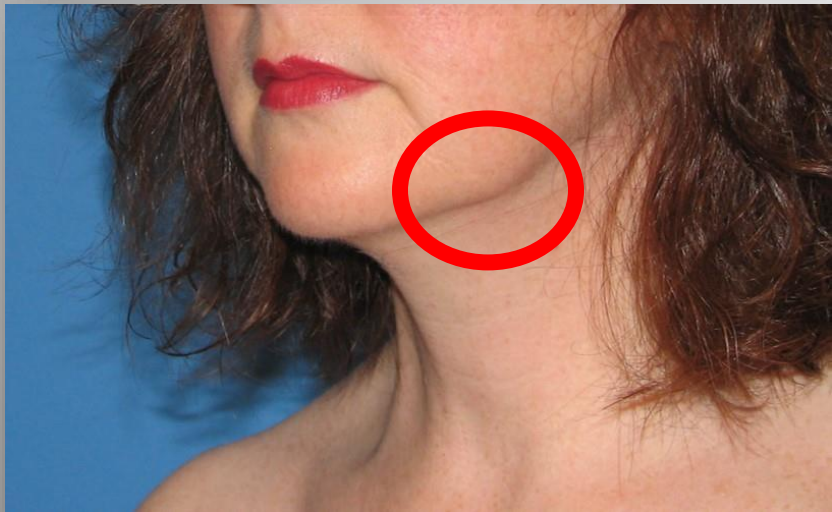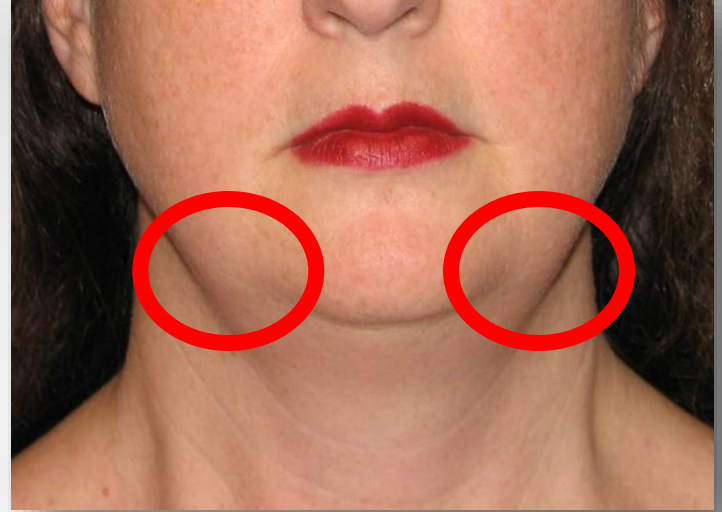
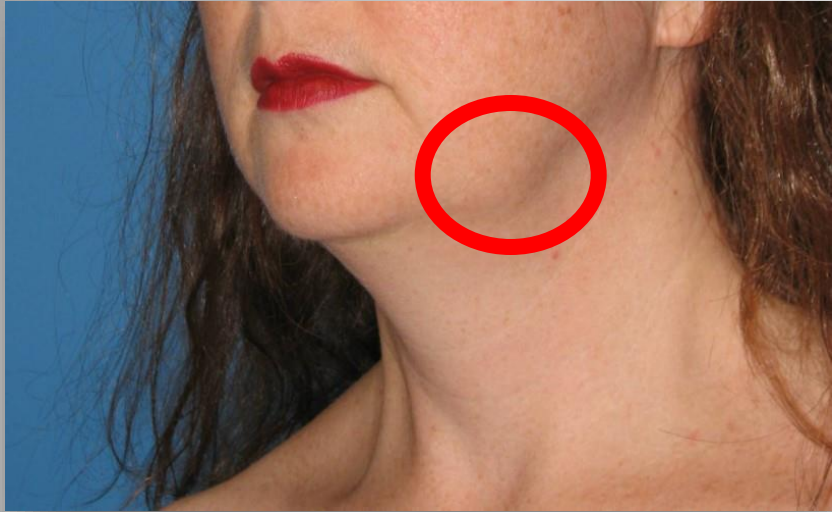
Liposuction



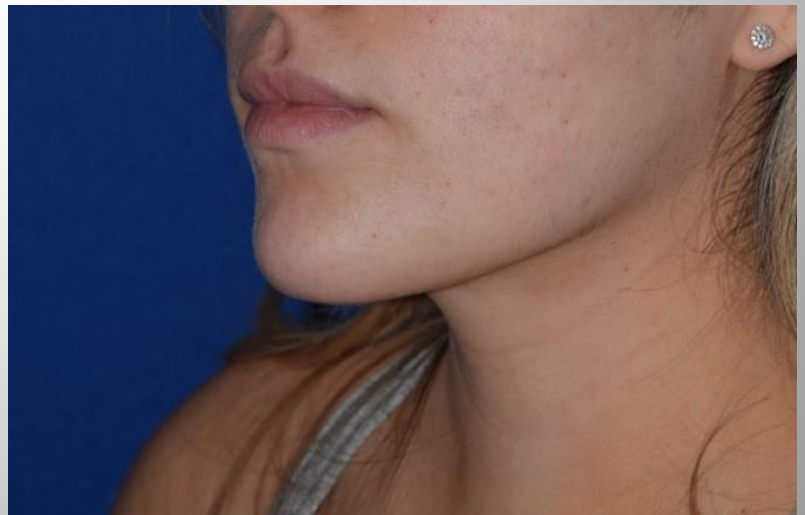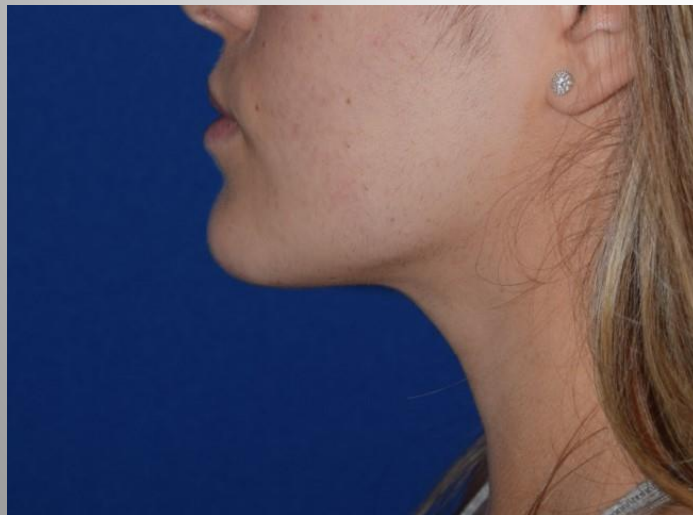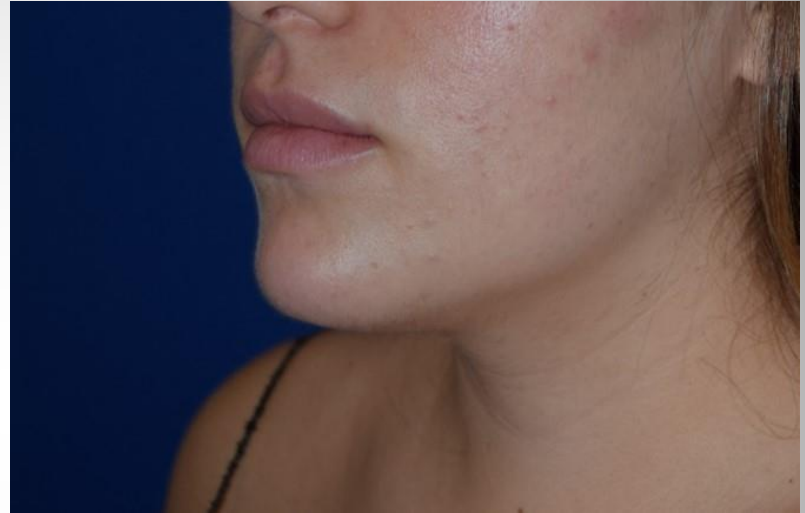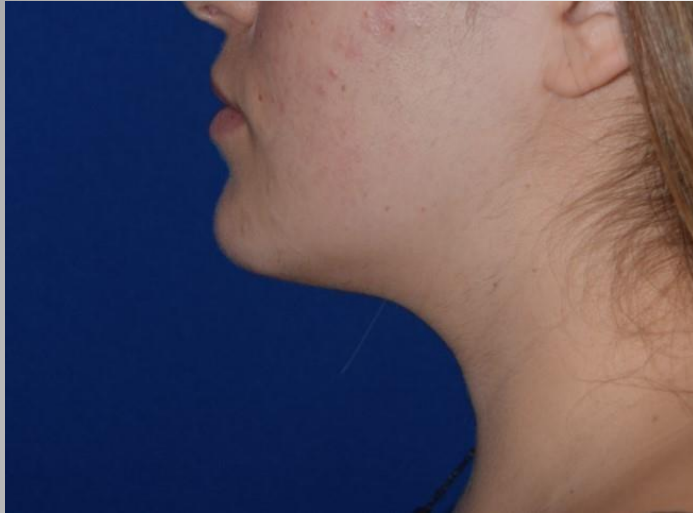Liposuction



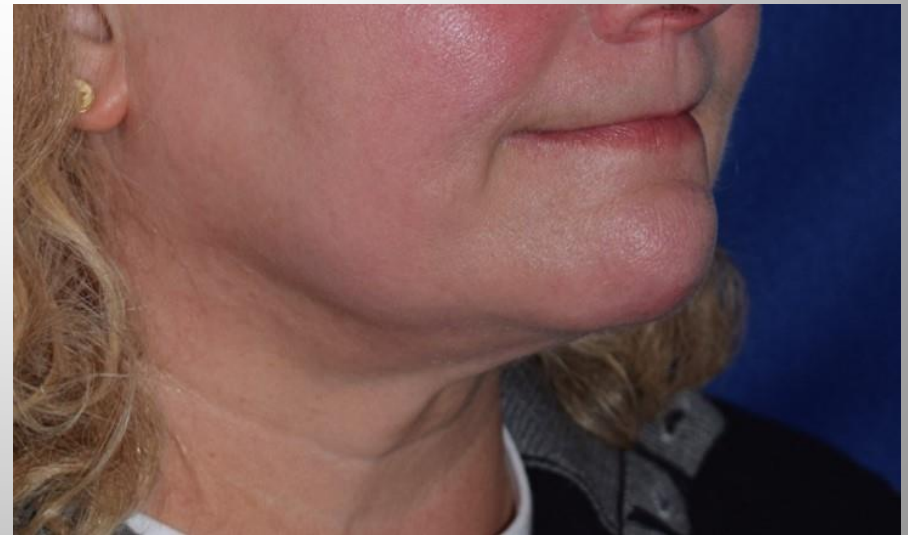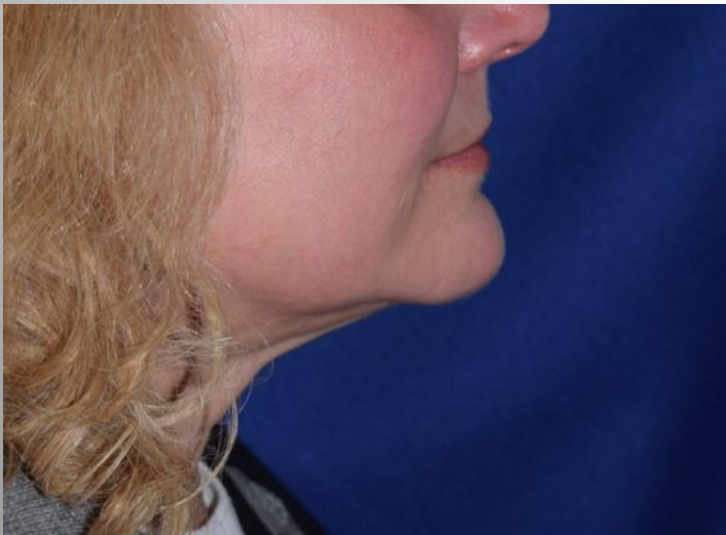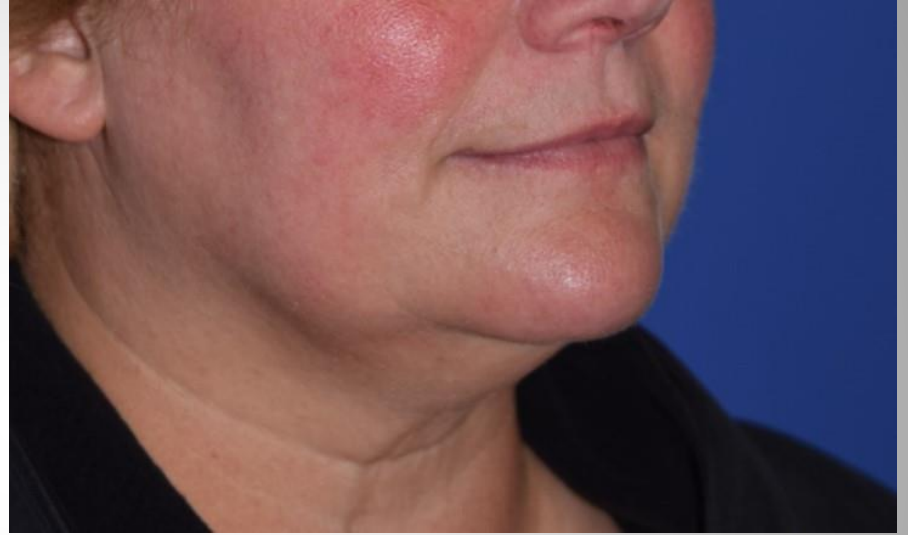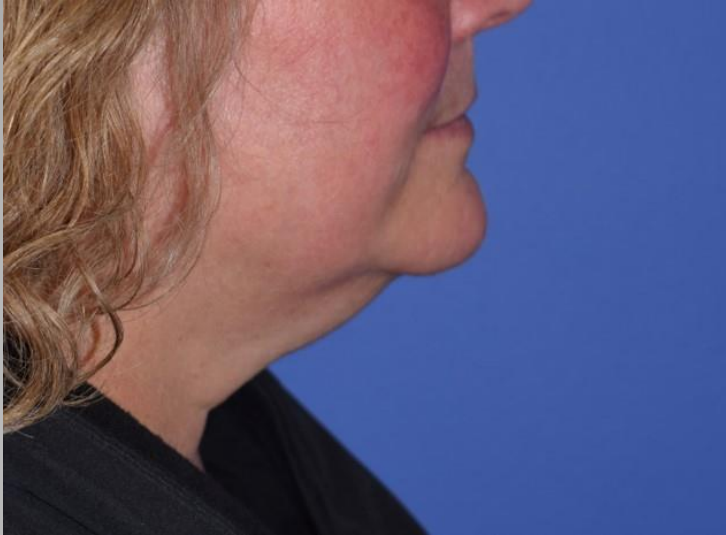Liposuction



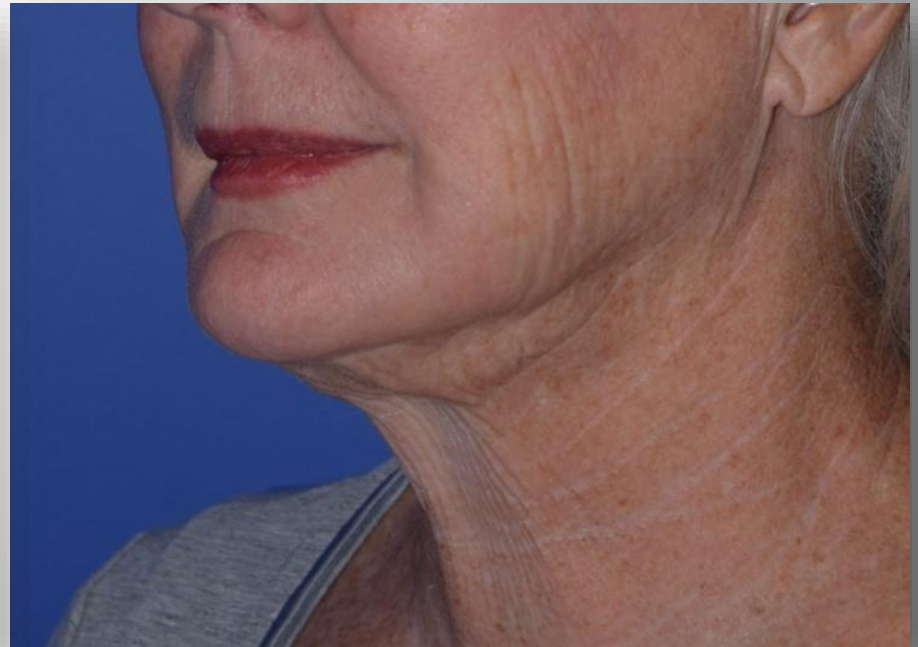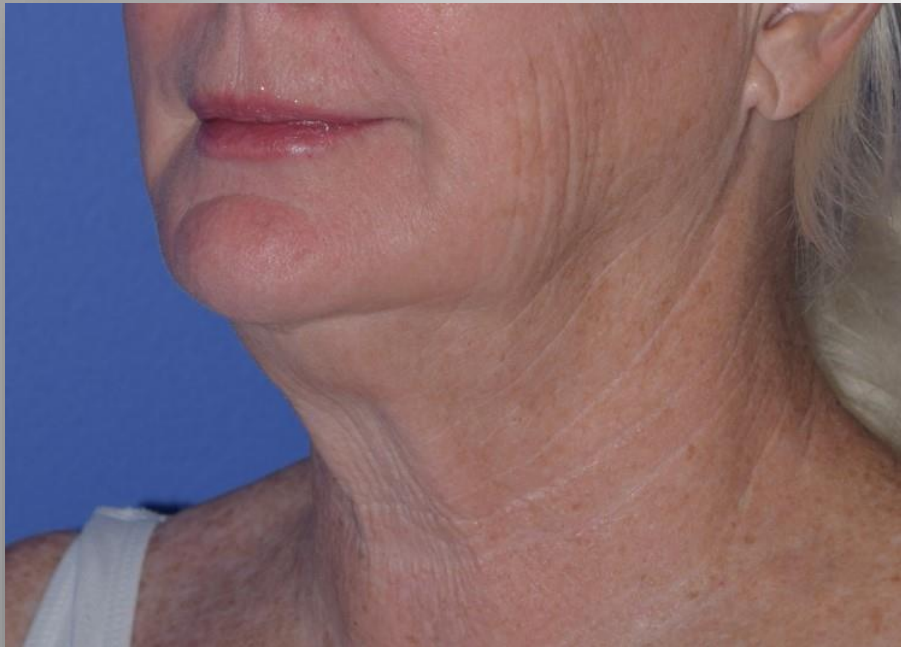Laser Assisted Liposuction



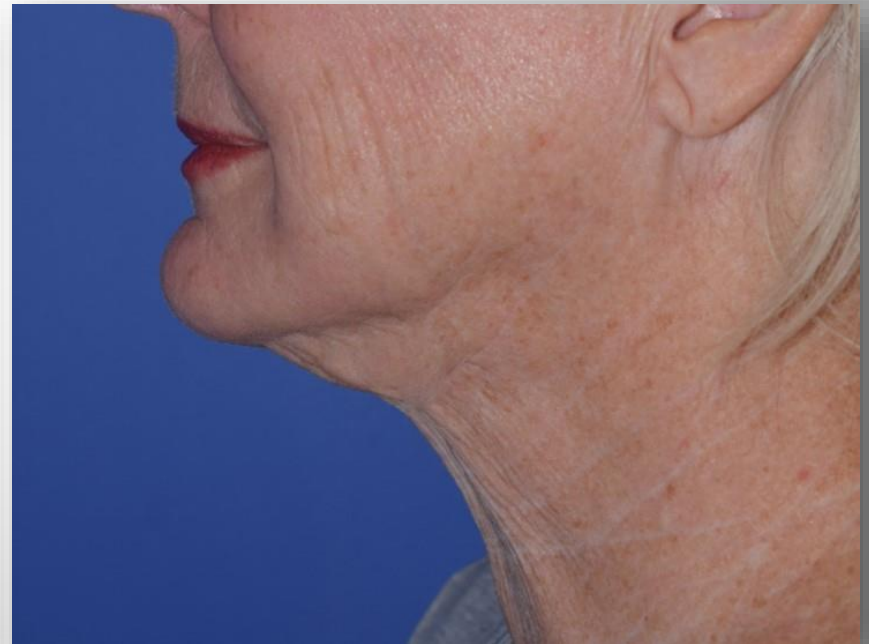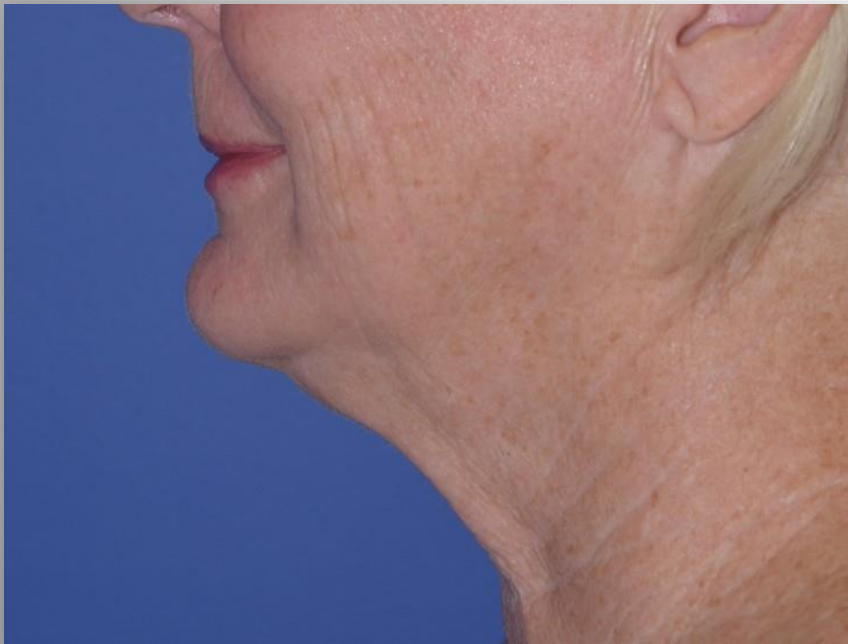Laser Assisted Liposuction



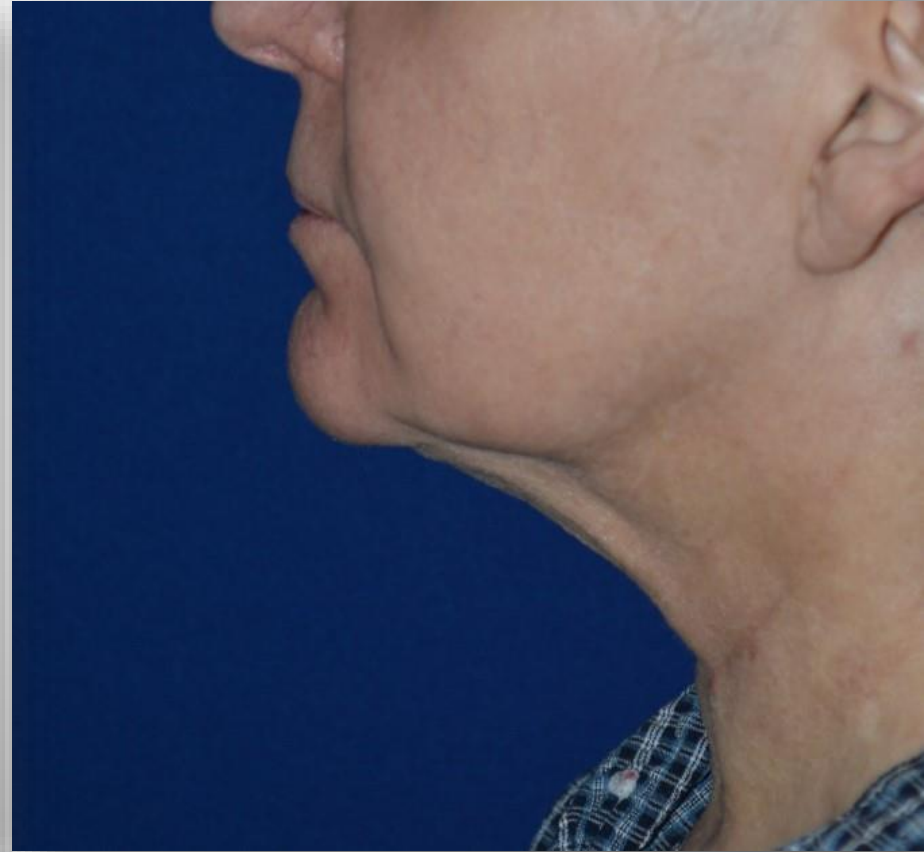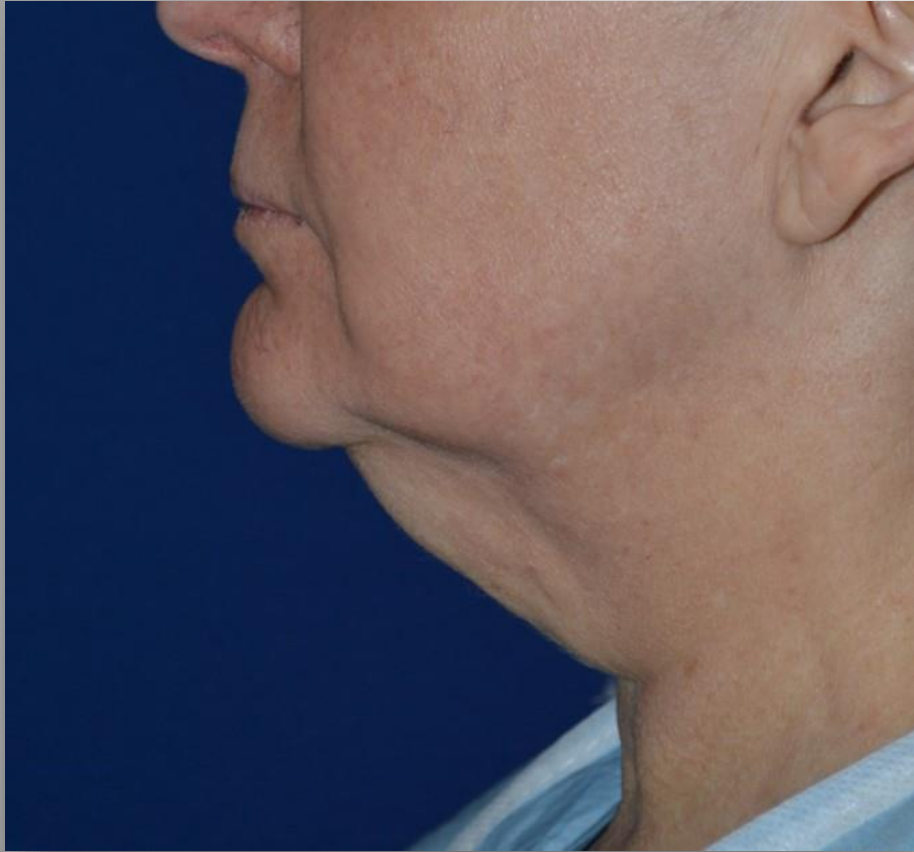
Laser Assisted Liposuction



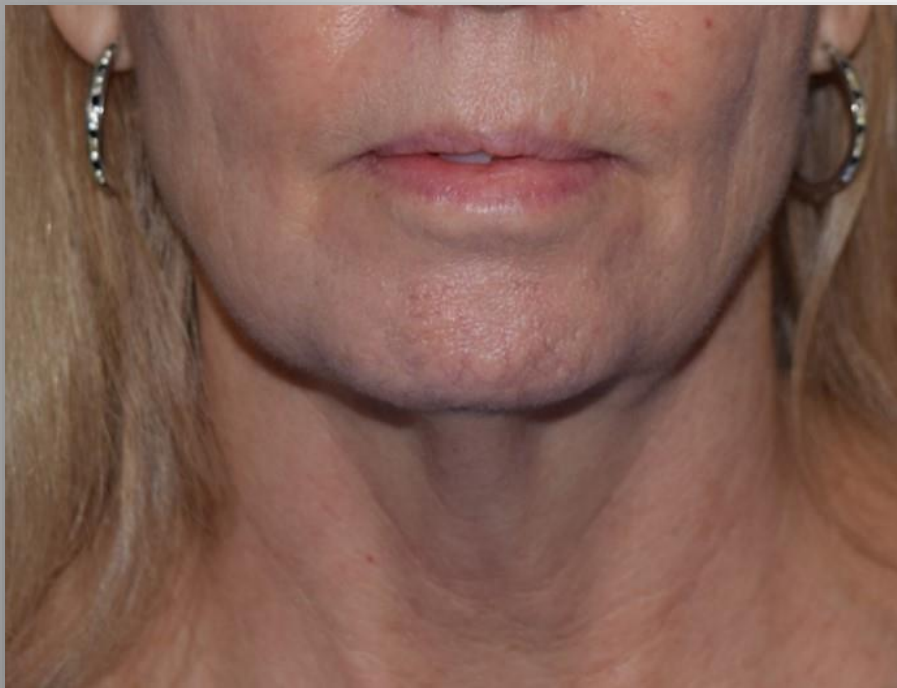Laser Assisted Liposuction



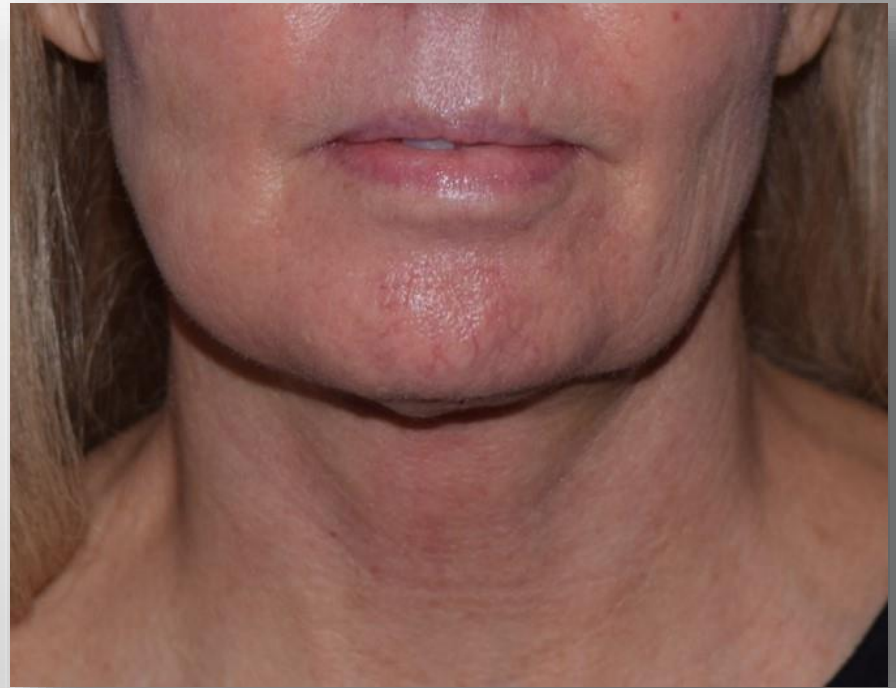Laser Assisted Liposuction



Laser Assisted Liposuction

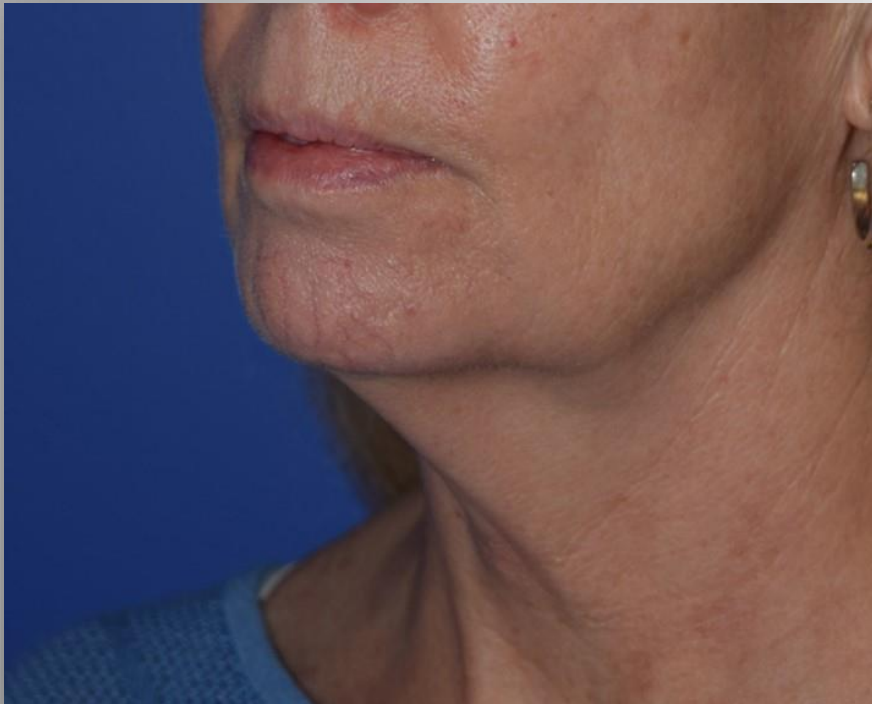

After Failed Ulthera
Treatment

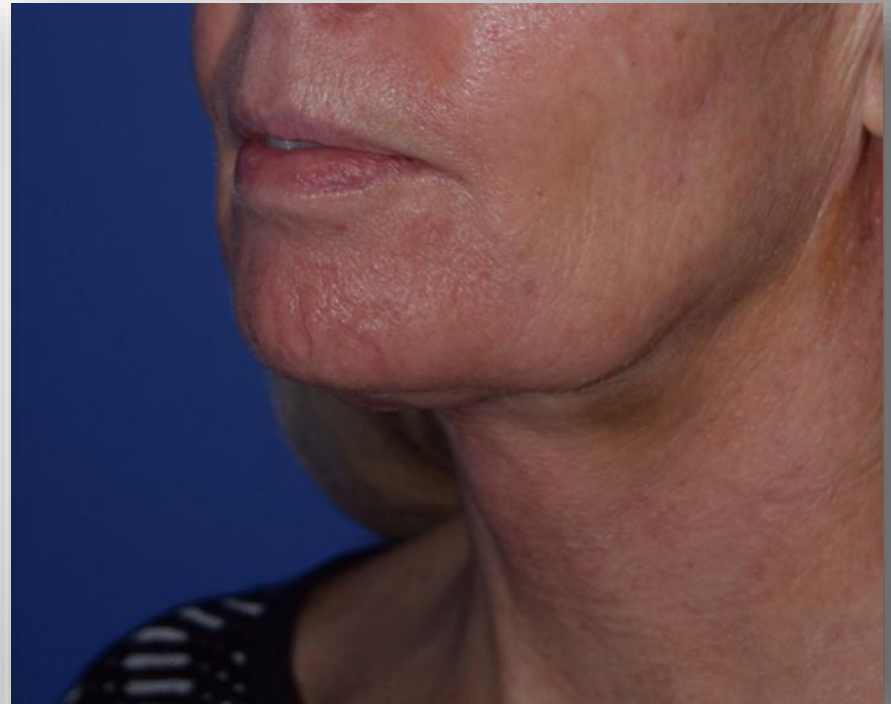

1 Week After Neck LAL

Laser Assisted Liposuction

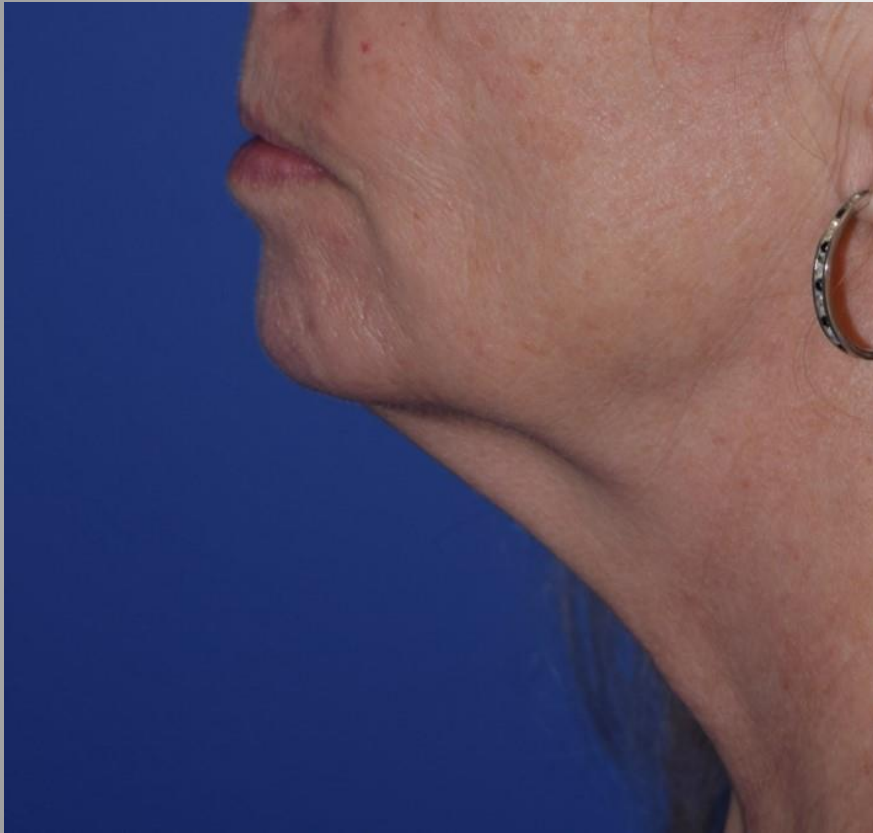

After Failed Ulthera
Treatment

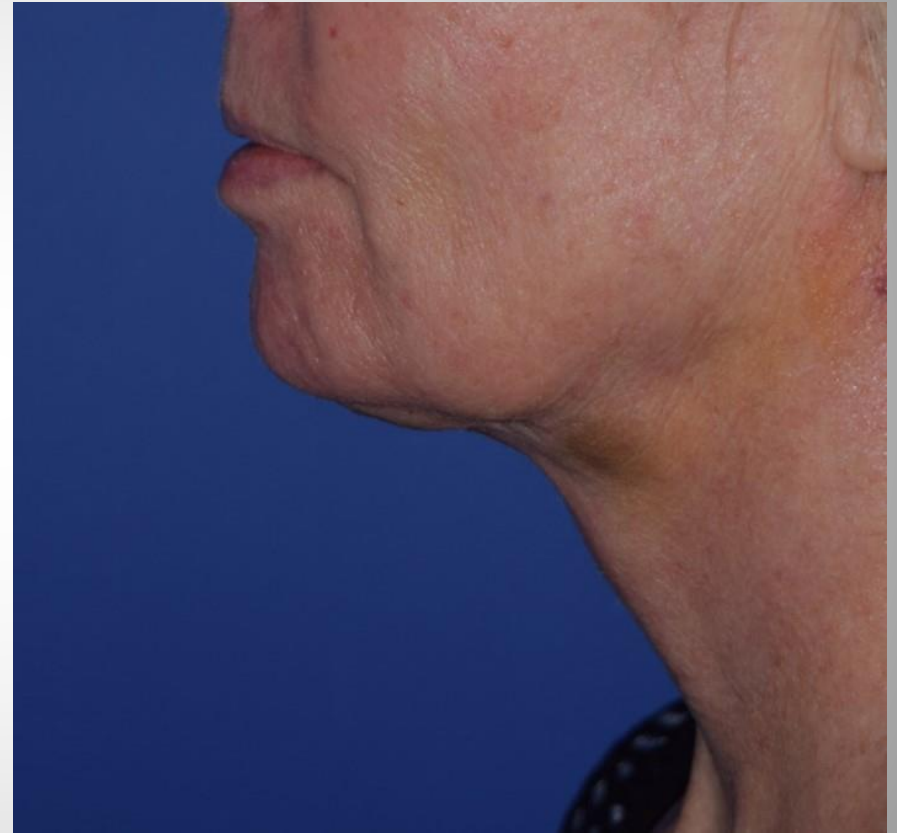

1 Week After Neck LAL

Laser Assisted Liposuction

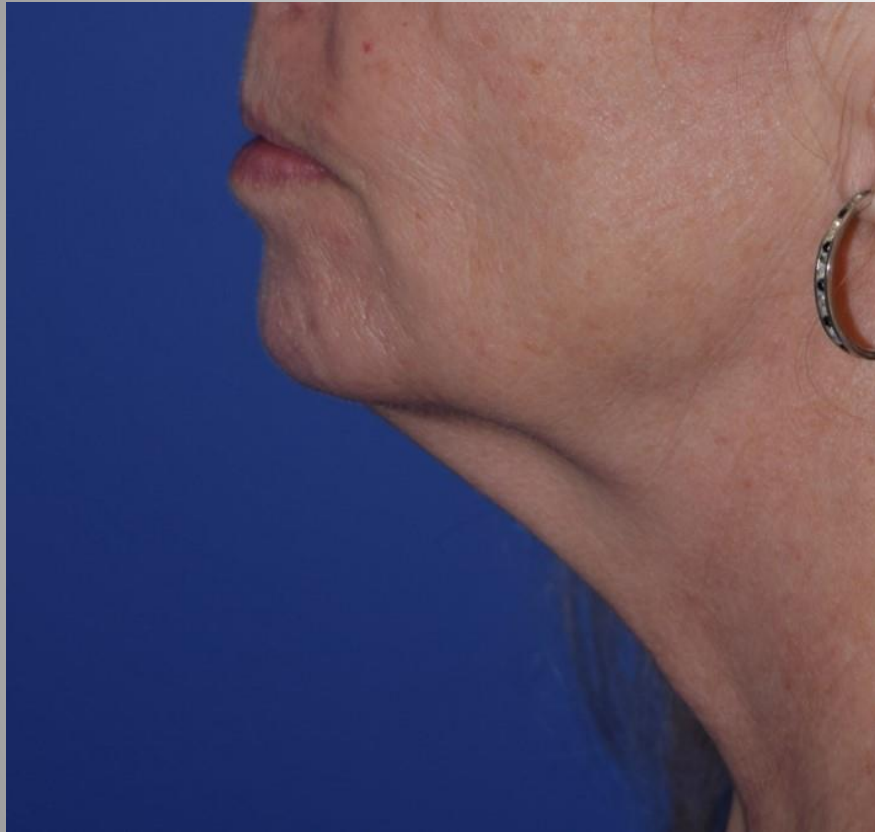

After Failed Ulthera
Treatment

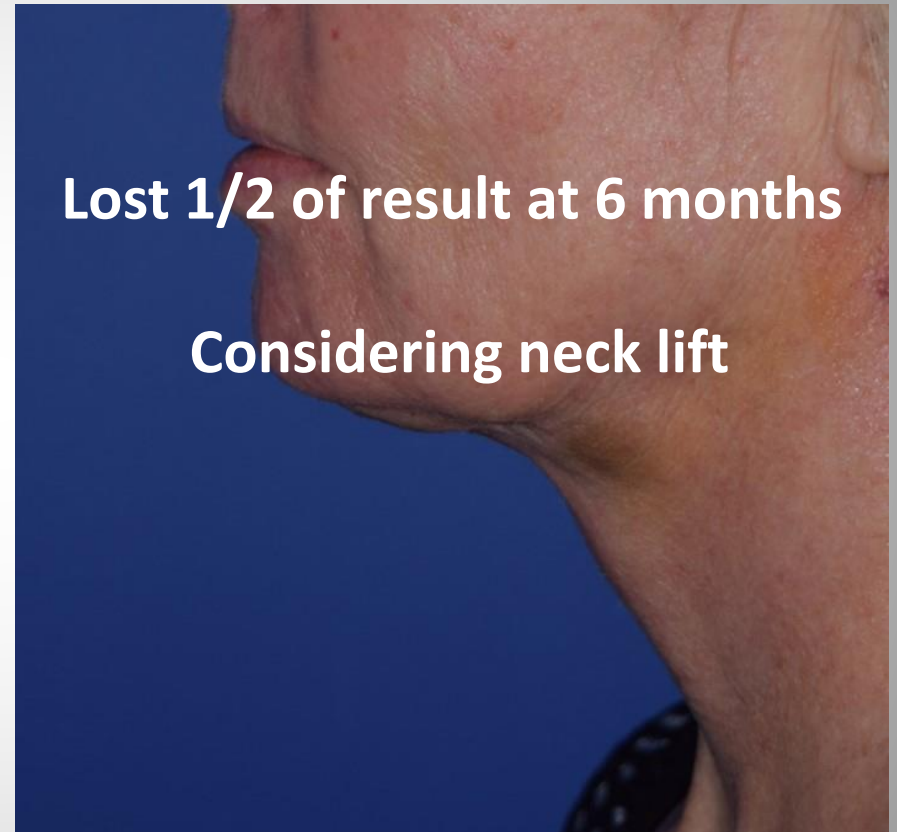

1 Week After Neck LAL

Laser Assisted Liposuction



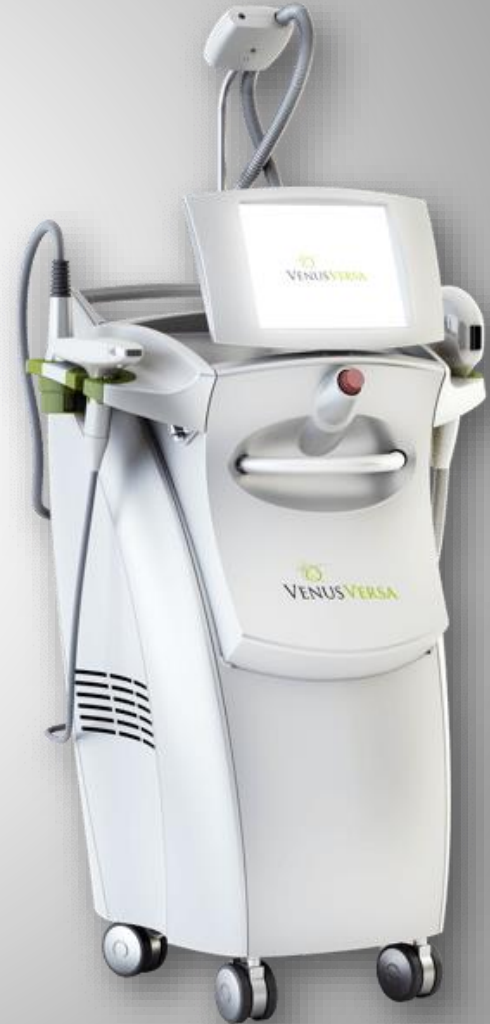After Failed Ulthera
Treatment



1 Week After Neck LAL

External Radio Frequency

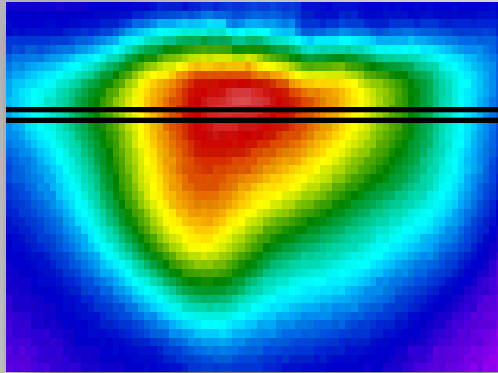
- Many devices
- Range of energy delivered
- Heat causes
 - Collagen tightening & stimulation
 - Fat reduction
- Multiple treatments
 - More than you think
 - Patient ability to tolerate the heat
- Be prepared for no results



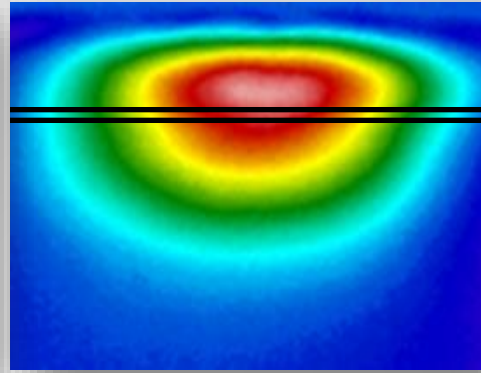
External Radio Frequency

Skin surface

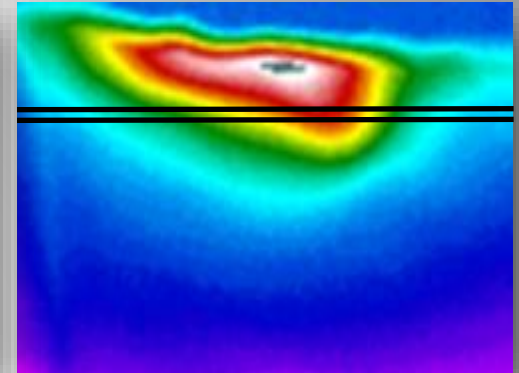
Hypodermis



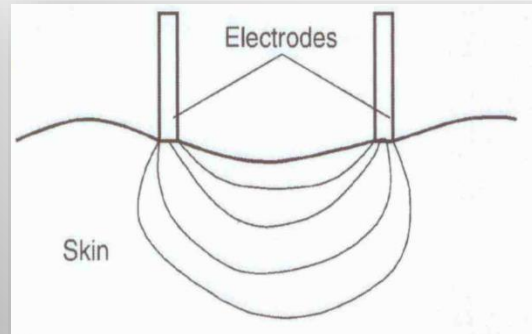
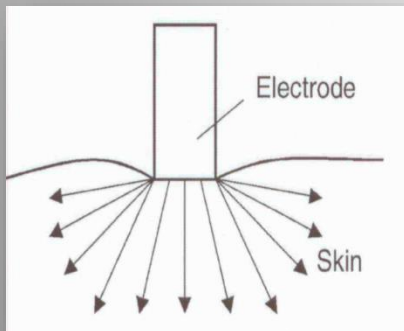
0.8 Mhz



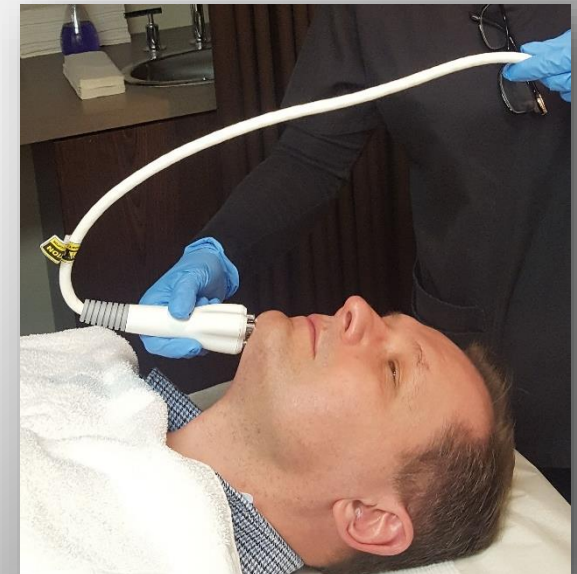
1.7 Mhz



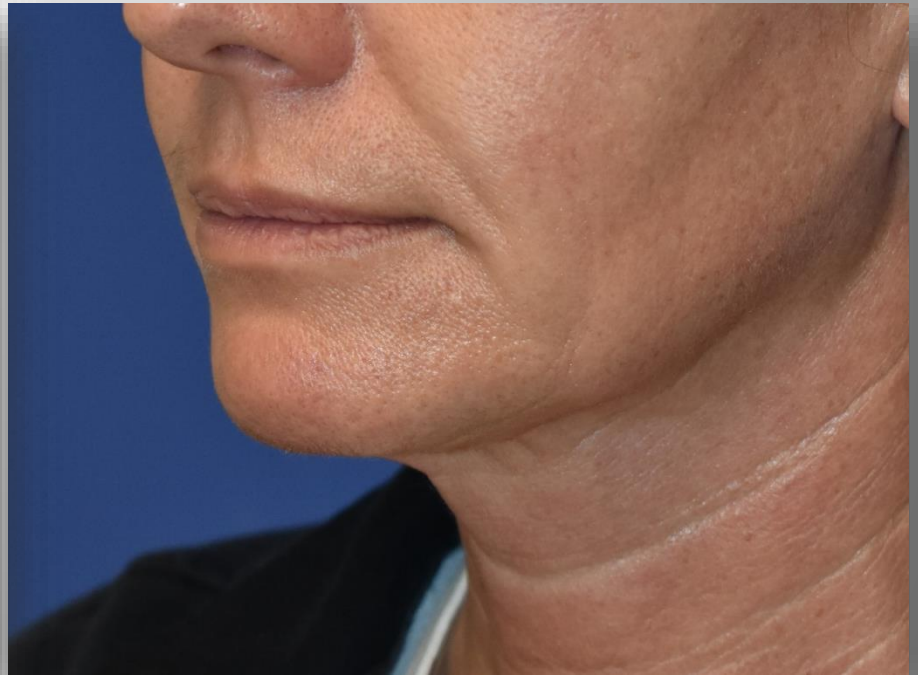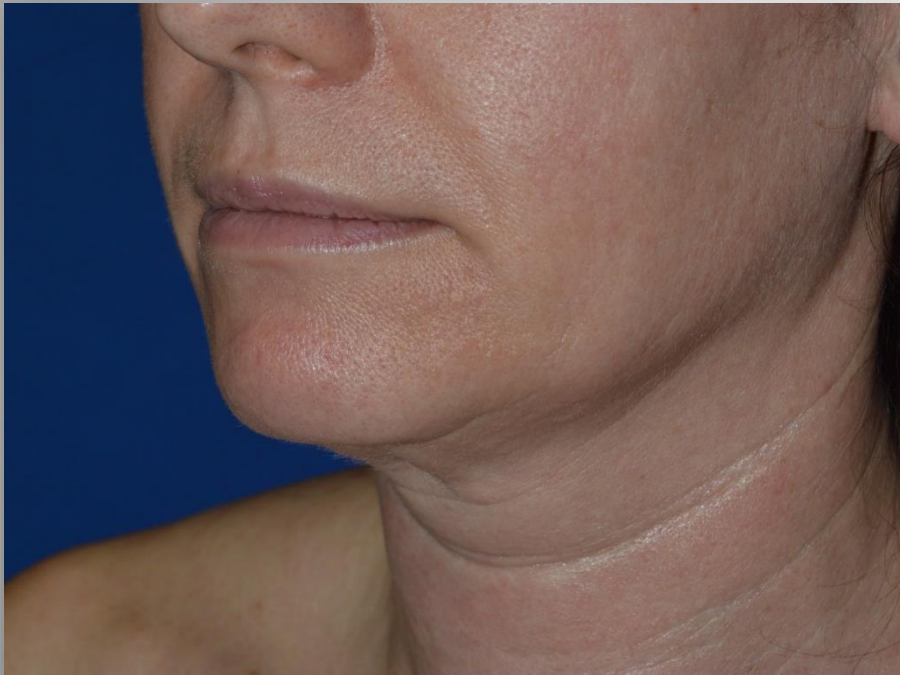2.5 Mhz



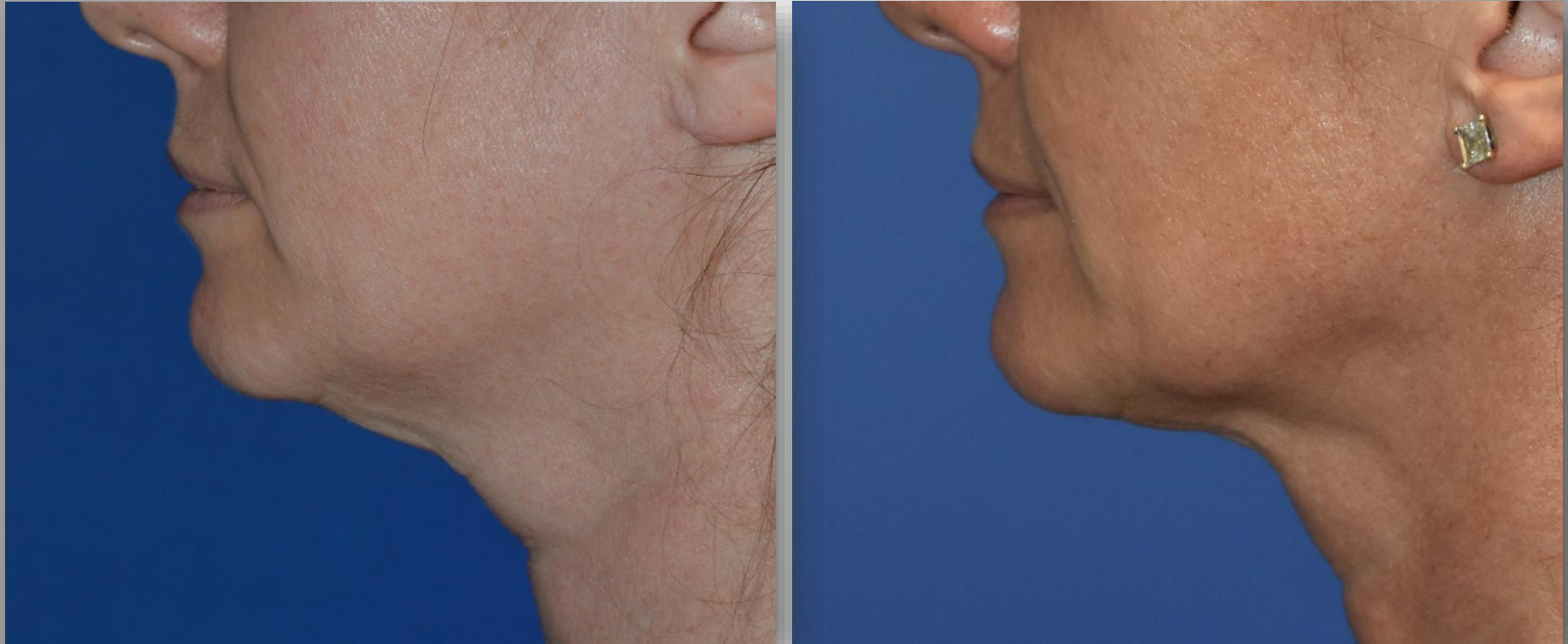Unipolar vs Bipolar vs Multipolar



Results After 3 Years



Results After 3 Years



Liposuction

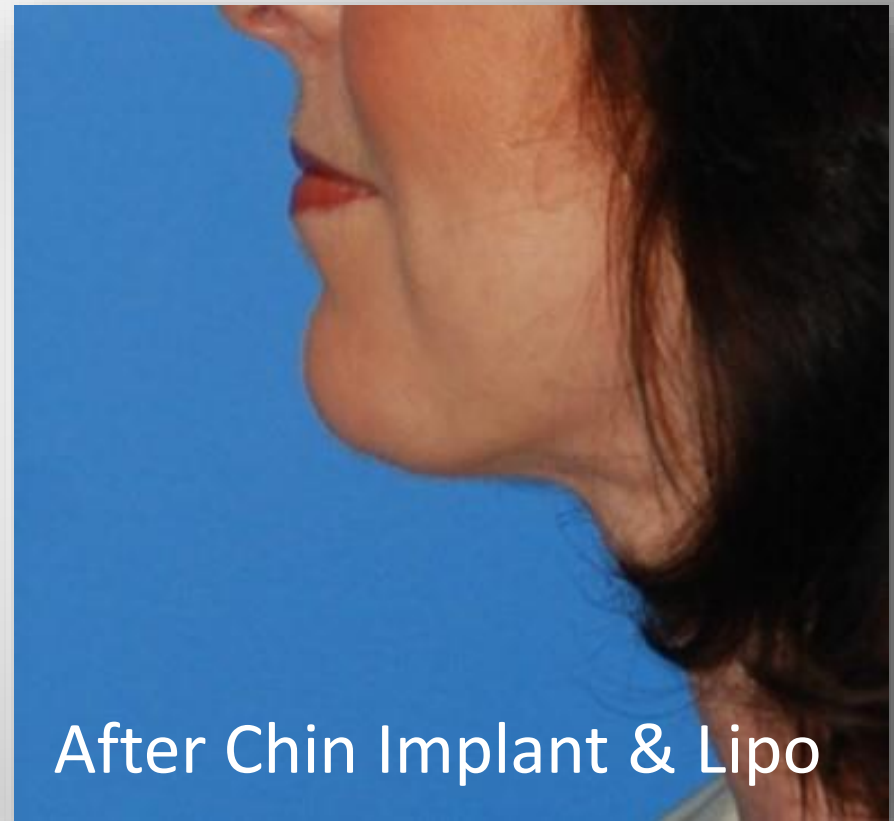
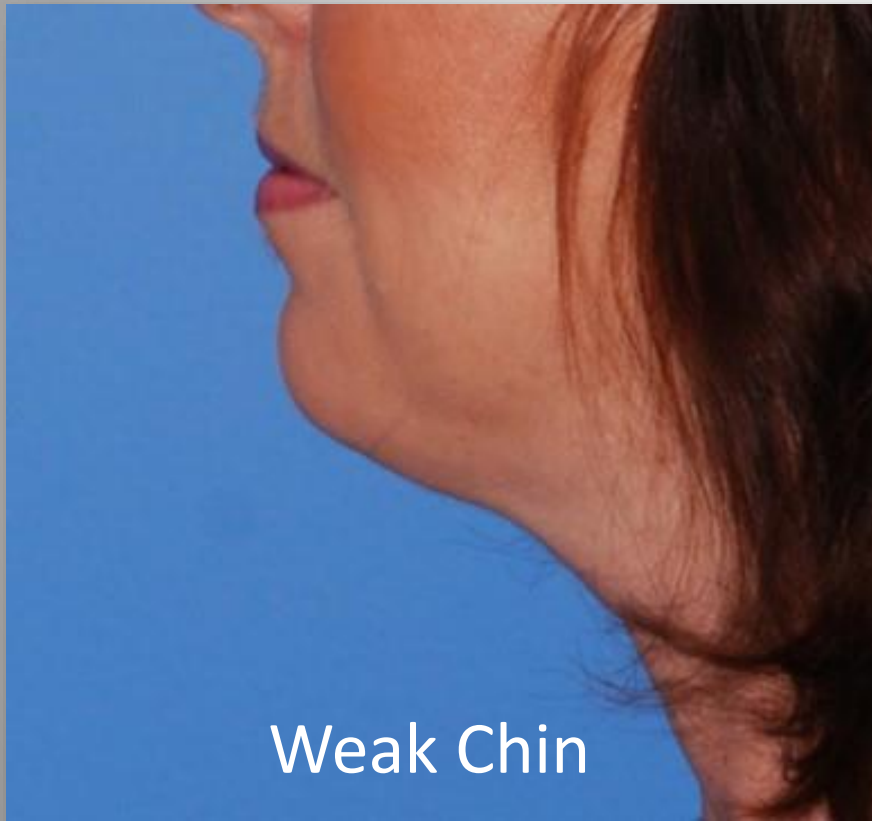
Standard Liposuction

- Easy
- Fast
- Can target fat zones
- Predictable
- Fast recovery
- Low cost
- Skin laxity not addressed

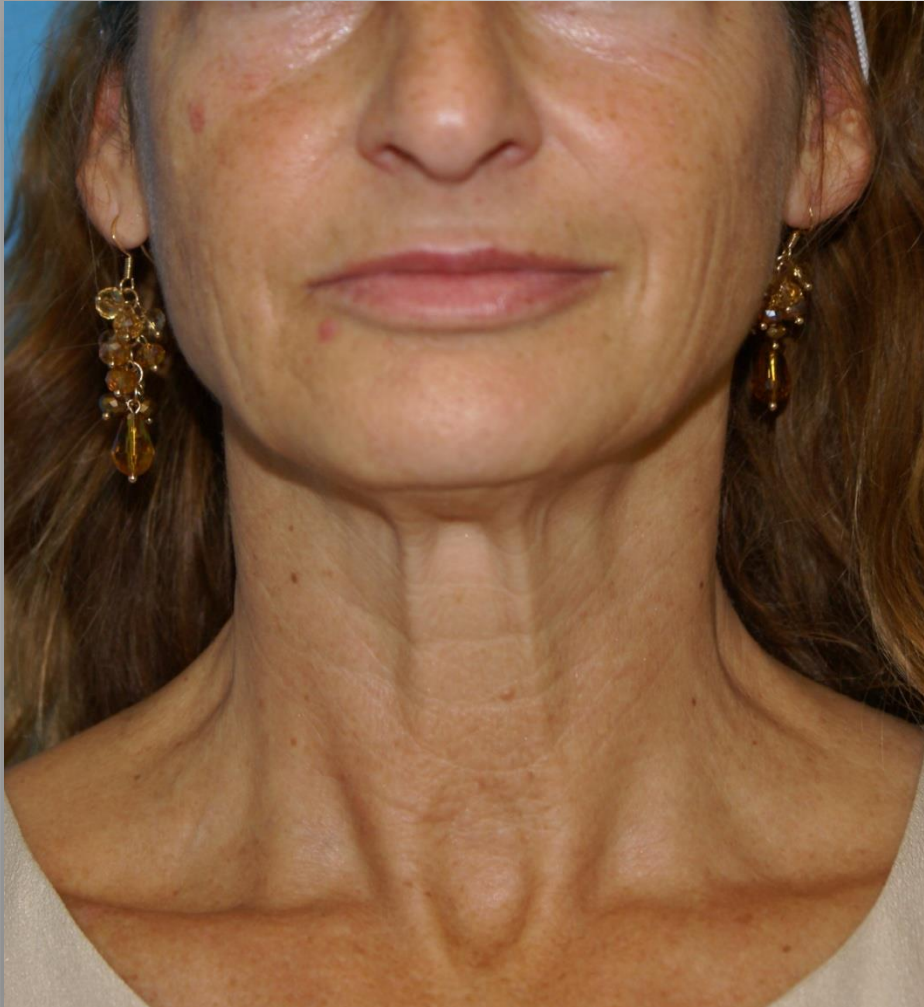Laser Assisted Liposuction

- Easy
- Fast (neck only)
- Can target fat zones
- Predictable
- Fast recovery
- Expensive
- Does tighten skin
- Prolonged inflammation
- More neuropraxia?

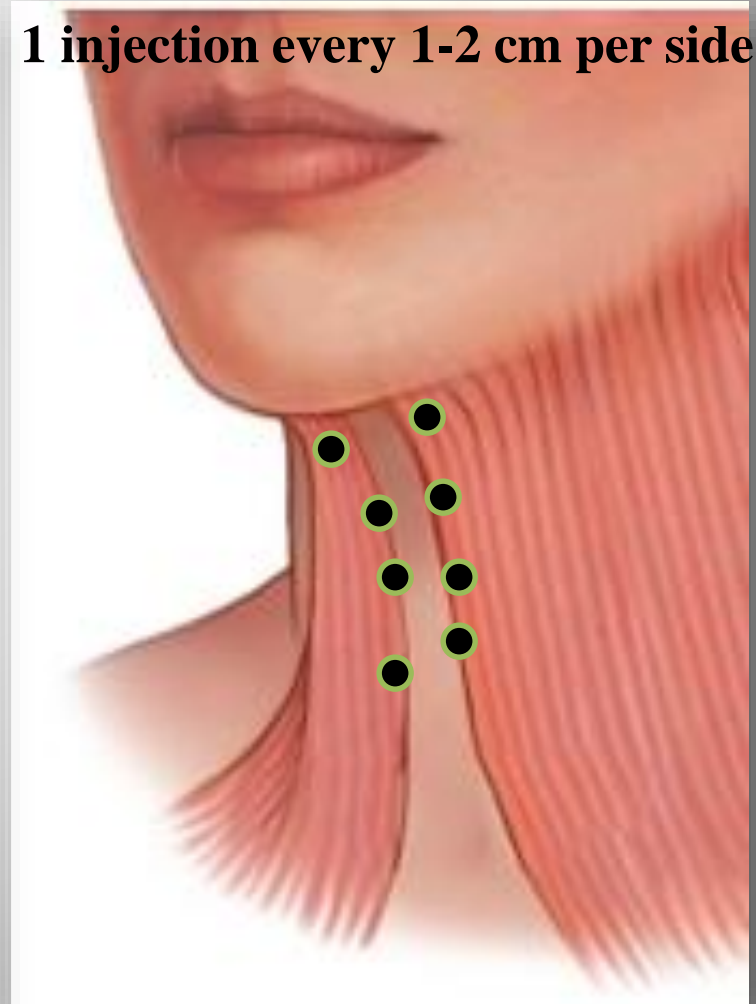Chin & Mandible: Implants



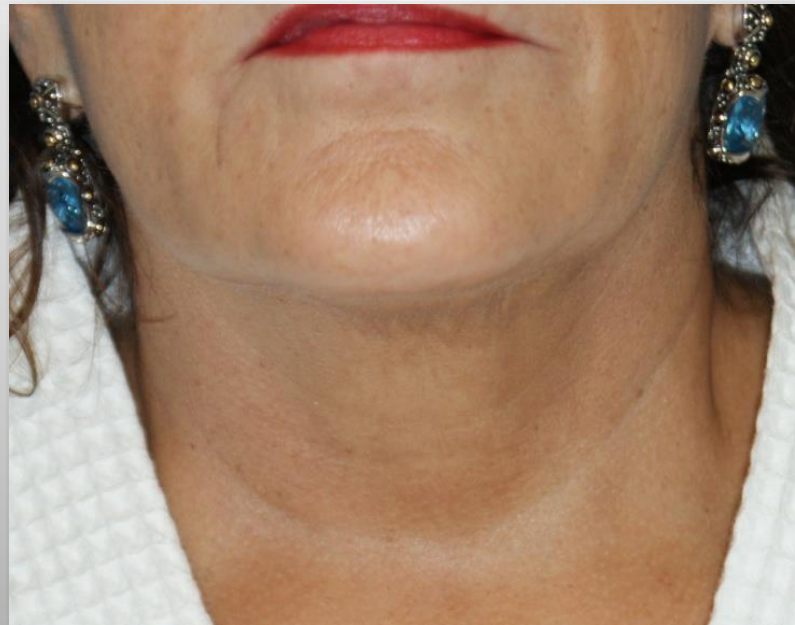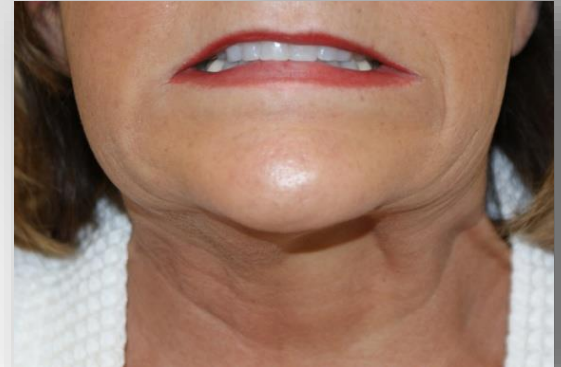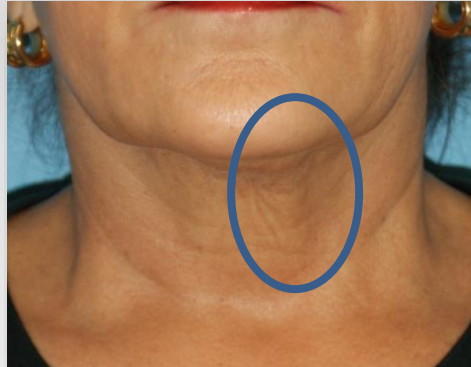
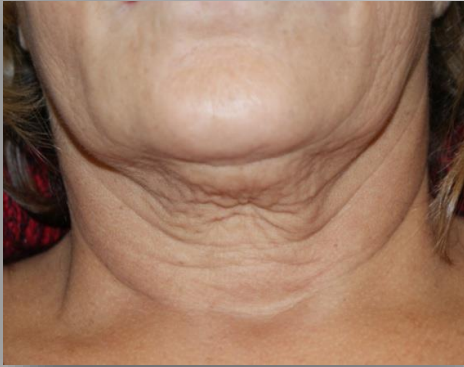Platysmal Band Neuromodulation



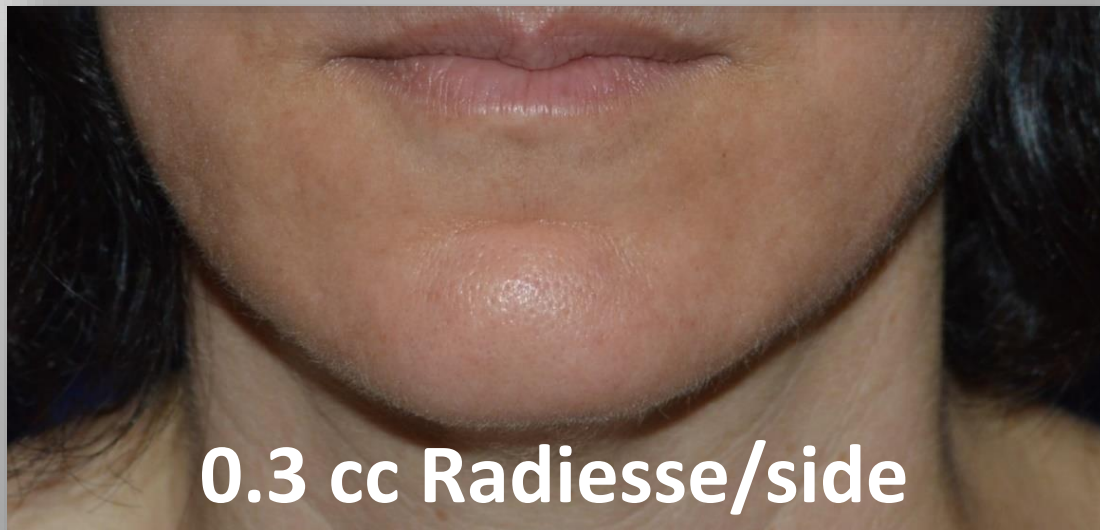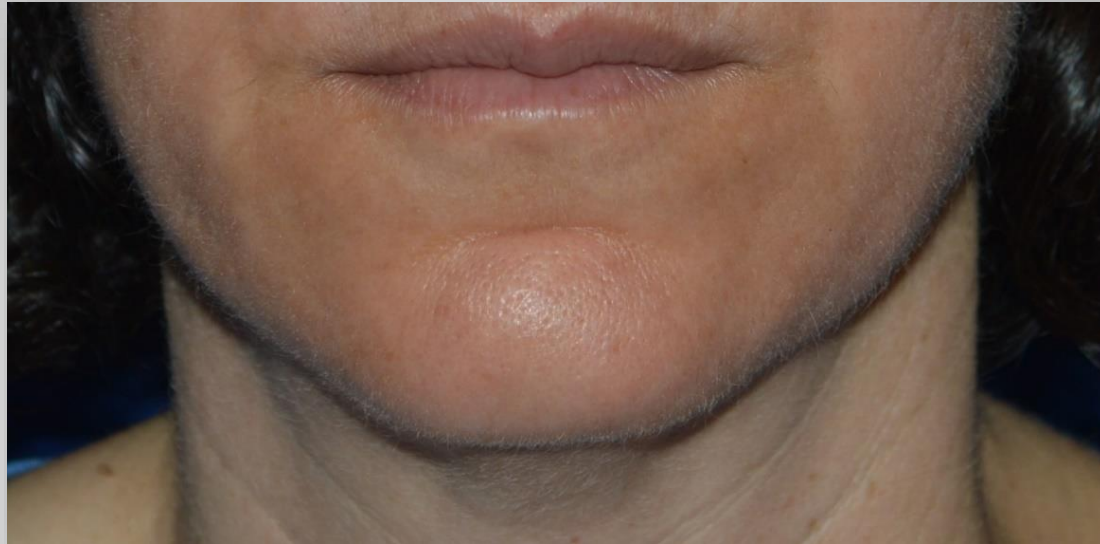1 injection every 1-2 cm per side



Annoying Platysma



Address Jaw Line & Pre Jowl Sulcus

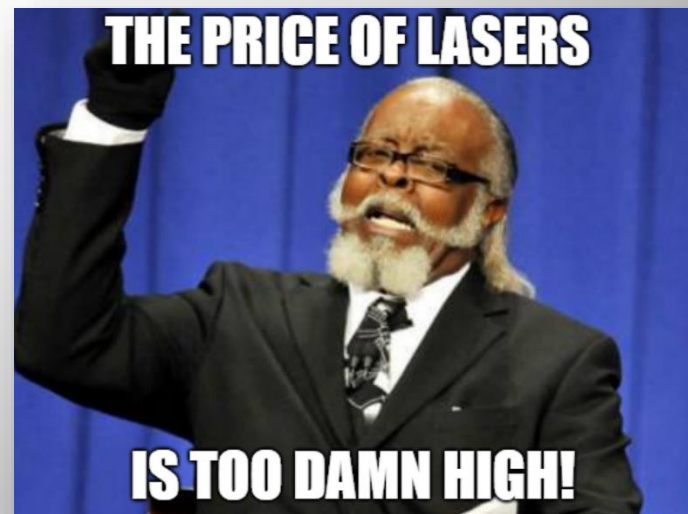


0.3 cc Radiesse/side

Lessons Learned

- Patients are looking for less expensive & less downtime procedures
 - Don't need “home run” results
 - Highest patient satisfaction procedure I offer
- Does the “Laser” really matter
 - Sometimes.....

**Consider sharing this
expensive device**



Summary

- Neck Skin
 - Basic skin care modalities
 - Micro needling may be an inexpensive tool
 - Non-ablative & ablative energy devices
- Neck fat - Limited
 - CoolSculpting if central
 - Kybella if central
 - Careful in older patients with loose skin

Summary

- Neck fat - Larger areas
 - Liposuction
 - Laser assisted liposuction for skin tightening
 - Liposuction allows best jawline definition
- Add additional treatments as needed
 - Implants
 - Fillers
 - Neuromodulators
 - Kybella

Neck Rejuvenation: More Options

Plast Reconstr Surg 2006

SPECIAL TOPIC

Neck Rejuvenation Revisited

Rod J. Rohrich, M.D.
Jose L. Rios, M.D.
Paul D. Smith, M.D.
Karol A. Gutowski, M.D.

*Dallas, Texas; Tampa, Fla.; and
Madison, Wis.*

Purpose: Restoration of the aesthetic neck contour is an integral component of facial rejuvenation. Multiple deformities of the neck and chin complex can make treatment of the cervical region daunting. An algorithmic approach to neck rejuvenation based on individual anatomic and clinical analysis is prudent. The authors created a simplified anatomic approach to the most common cervical deformities encountered in the patient seeking facial rejuvenation.

- **Liposuction (Mostly LAL)**
- Chin Implant
- Neurmodulator
- Neck +/- Face Lift

Neck Laser Assisted Liposuction: Lessons Learned

Karol A Gutowski, MD, FACS

Karol@DrGutowski.com

773-870-0732

Copy of this presentation

DrGutowski.com ➡ For Physicians

26th State-of-the-Art in Facial
Aesthetics

Jung Hotel,
New Orleans, LA
March 28-31, 2019